



# An Atlas for the Foot Osteoarthritis Magnetic Resonance Imaging Score (FOAMRIS)

Jill Halstead, Jennifer Jones, Carmen Martin-Hervas, John Arnold, Heidi Siddle, Anne-Maree Keenan,  
Anthony Redmond

Leeds Institute of Rheumatic and Musculoskeletal Medicine and National Institute of Health  
Research Leeds Biomedical Research Centre

## Preface and Background

This atlas was compiled to further research into foot pain and osteoarthritis (OA). The atlas was created from an amalgamation of research studies which aimed to explore and expand research in the midfoot and associated interventions. The images utilised were sourced from a mechanical foot pain study (doctoral thesis) and the Leeds OA Foot Study (fellowship study) both completed through the Section of Biomechanics and Physical Medicine at the University of Leeds. This study was led by Professor Anthony Redmond<sup>1-4</sup>, Dr Jill Halstead<sup>1,5</sup> (visiting fellow), Dr Carmen Martín-Hervás<sup>6</sup> (visiting fellow), Dr John Arnold<sup>7</sup> (visiting fellow) and Jennifer Jones<sup>1,5</sup> (Versus Arthritis internship) and supported by Professor Heidi Siddle<sup>1-2</sup> and Professor Keenan<sup>1-2</sup>.

This atlas was compiled from 158 magnetic resonance images (MRIs). The sample included purposive sampling from publicity campaigns, community Podiatry and Physiotherapy services and hospital rheumatology services. This included people without pain, people with foot pain and people with radiographic confirmed foot OA. The FOAMRIS atlas was created to support the use of the MRI score, images were selected from a total of 158 MRIs, 35 were pain-free and no known OA, 69 had foot pain and 54 had symptomatic radiographic foot OA (access through Leeds Repository <https://doi.org/10.5518/1568>).

The sample was unsuccessful at capturing certain features at higher grades (highlighted in the table below) and therefore the atlas is published incomplete (greyed out scores). The failure to identify some of the larger graded imaging features suggests some features may be less prevalent, associated with trauma, stress and or morphological variations.

### *Acknowledgements*

This atlas would not be possible without the time of the participants and the financial support of Versus Arthritis, National Institute for Health and Care Research (NIHR), NIHR Leeds Biomedical Research Centre and National Health and Medical Research Council Early Career Fellowship.

We would like to acknowledge the contributions of Dr Eiji Fukuba and Dr Carmen Martín-Hervás musculoskeletal radiologists, who were involved in the development of the foot OA MRI score. We would also like to acknowledge the expertise of Dr Richard Hodgson, Rob Evans and Dr Carole Burnett of the NIHR Leeds Biomedical Research Centre in the acquisition of MRIs. We would like to acknowledge the contribution and time of Madeleine Schaper who has identified MRIs for this atlas.

### *Affiliations*

1 Leeds Institute of Rheumatic and Musculoskeletal Medicine, University of Leeds, UK

2 NIHR Leeds Biomedical Research Centre, Leeds Teaching Hospitals Trust, Leeds, UK

3 Arthritis Research UK Experimental Osteoarthritis Treatment Centre, Leeds, UK.

4 Arthritis Research UK Centre for Sports, Exercise and Osteoarthritis, Nottingham/Leeds, UK.

5 Leeds Community Healthcare NHS Trust, Leeds, UK

6 Radiology Department, La Paz University Hospital, Autonomous University of Madrid, Spain

7 University of South Australia, Adelaide, South Australia.



*Correspondence*

Professor Redmond

Dr Jill Halstead-Rastrick

[a.redmond@leeds.ac.uk](mailto:a.redmond@leeds.ac.uk)

[j.halstead-rastrick@leeds.ac.uk](mailto:j.halstead-rastrick@leeds.ac.uk)

### Atlas Imaging Features Missing

Forefoot		
Feature	Image sequence	Grade
Representative Lesser Toe Metatarso-phalangeal Joint Bone Marrow Lesion	T2w Long Axis	3
	T2w Sagittal	3
Metatarsal Distal Shaft Bone Marrow Lesion	T2w Long Axis	2 & 3
	T2w Sagittal	2 & 3
Metatarsal Central Shaft Bone Marrow Lesion	T2w Long Axis	3
	T2w Sagittal	3
Metatarsal Proximal Shaft Bone Marrow Lesion	T2w Long Axis	3
	T2w Sagittal	3
Midfoot		
Feature	Image sequence	Grade
1st Tarso-metatarsal Joint Bone Marrow Lesion	T2w Long Axis	3
	T2w Sagittal	3
5th Tarso-metatarsal Joint Osteophytes	T1w Long Axis	3
	T1w Sagittal	3
5th Tarso-metatarsal Joint Bone Marrow Lesion	T2w Long Axis	2 & 3
	T2w Sagittal	2 & 3
Tarso-metatarsal exemplar Bone Erosion	T1w Long Axis	3
	T1w Sagittal	3
Navicular Bone Marrow Lesion	T2w Long Axis	3
	T2w Sagittal	3
Intermediate Cuneiform Bone Marrow Lesion	T2w Long Axis	3
	T2w Sagittal	3
Cuboid Bone Marrow Lesion	T2w Long Axis	3
	T2w Sagittal	3
Hindfoot		
Feature	Image sequence	Grade
Naviculo-medial cuneiform Joint Space Narrowing	T2w Long Axis	3
	T1w Sagittal	3
Naviculo-medial Cuneiform Osteophytes	T1w Sagittal	3
Soft Tissues		
Feature	Image sequence	Grade
Tibialis Anterior Tenosynovitis	T2w Sagittal	3
	T2w Short Axis	3
Extensor Hallucis Longus Tenosynovitis	T2w Sagittal	2 & 3
	T2w Short Axis	2 & 3
Tibialis Posterior Tenosynovitis	T2w Sagittal	3
	T2w Short Axis	3
Extensor Digitorum Longus Tenosynovitis	T2w Sagittal	3
	T2w Short Axis	3
<b>Total 17 features missing, 6 were grade 2 and 3, 11 were grade 3</b>		

## Table of Contents

<b>Chapter 1. Definitions and Score sheet .....</b>	<b>11</b>
<b>Definitions.....</b>	<b>12</b>
Joint space narrowing (JSN) .....	12
Osteophytes .....	12
Effusion-synovitis .....	12
Subchondral cyst .....	12
Bone marrow lesion (BML).....	13
Bone erosion .....	13
Enthesopathy .....	14
Sub-tendon Bone Marrow Lesion (BML).....	14
Tenosynovitis.....	14
Ligament abnormality .....	15
<b>Foot Osteoarthritis MRI Score Sheet.....</b>	<b>16</b>
<b>Chapter 2. Forefoot .....</b>	<b>20</b>
<b>First Metatarso-phalangeal Joint .....</b>	<b>21</b>
Joint Space Narrowing.....	21
Short tau inversion recovery Long axis .....	21
T1-weighted Sagittal plane.....	21
Osteophytes .....	22
T1-weighted Long axis.....	22
T1-weighted Sagittal plane.....	22
Effusion-Synovitis.....	23
Short tau inversion recovery Long axis .....	23
T2-weighted Sagittal plane.....	23
Subchondral Cyst.....	24
Short tau inversion recovery Long axis .....	24
T2-weighted Sagittal plane.....	24
Bone Marrow Lesion Metatarsal Head .....	25
T2-weighted Long axis.....	25
T2-weighted Sagittal plane.....	25
Bone Marrow Lesion Phalanx Base .....	26
T2-weighted Long axis.....	26
T2-weighted Sagittal plane.....	26
<b>Representative Lesser Toe Metatarso-phalangeal Joint .....</b>	<b>27</b>
Joint Space Narrowing.....	27
Short tau inversion recovery Long axis .....	27
T1-weighted Sagittal plane.....	27
Osteophytes .....	28
T1-weighted Long axis.....	28
T1-weighted Sagittal plane.....	28
Effusion-Synovitis.....	29
T2-weighted Long axis.....	29
T2-weighted Sagittal plane.....	29
Subchondral Cyst.....	30
Short tau inversion recovery Long axis.....	30
T2-weighted Sagittal plane.....	30
T1-weighted Sagittal plane.....	30
Bone Marrow Lesion at Metatarsal Head and or Phalanx Base.....	31
T2-weighted Long axis.....	31
T2-weighted Sagittal Plane.....	31
Bone Erosion at Metatarsal Head and or Phalanx Base.....	32

T1-weighted Long axis .....	32
T1-weighted Sagittal plane.....	32
<b>Representative Metatarsal Bone Score.....</b>	<b>33</b>
Bone Marrow Lesion at Distal Shaft Bone.....	33
T2-weighted Long axis.....	33
T2-weighted Sagittal plane.....	33
Bone Marrow Lesion at Central Shaft Bone .....	34
T2-weighted Long axis.....	34
T2-weighted Sagittal plane.....	34
Bone Marrow Lesion at Proximal Shaft Bone .....	35
T2-weighted Long axis.....	35
T2-weighted Sagittal plane.....	35
<b>Chapter 3. Midfoot and Hindfoot.....</b>	<b>36</b>
<b>First Tarso-metatarsal Joint .....</b>	<b>37</b>
Joint Space Narrowing.....	37
T2-weighted Long axis.....	37
T2-weighted Sagittal plane.....	37
Osteophytes .....	38
T1-weighted Sagittal plane.....	38
T1-weighted Long axis.....	38
Effusion-Synovitis .....	39
T2-weighted Long axis.....	39
T2-weighted Sagittal plane.....	39
Subchondral Cyst.....	40
T2-weighted Long axis.....	40
T1-weighted Sagittal plane.....	40
Bone Marrow Lesion .....	41
T2-weighted Long axis.....	41
T2-weighted Sagittal plane.....	41
<b>Second Tarso-metatarsal Joint.....</b>	<b>42</b>
Joint Space Narrowing.....	42
T2-weighted Long axis.....	42
T2-weighted Sagittal plane.....	42
Osteophytes .....	43
T1-weighted Long axis.....	43
T1-weighted Sagittal plane.....	43
Effusion-Synovitis .....	44
T2-weighted Long axis.....	44
T2-weighted Sagittal plane.....	44
Subchondral Cyst.....	45
T2-weighted Long axis.....	45
T1-weighted Sagittal plane.....	45
Bone Marrow Lesion .....	46
T2-weighted Long axis.....	46
T2-weighted Sagittal plane.....	46
<b>Third Tarso-metatarsal Joint.....</b>	<b>47</b>
Joint Space Narrowing.....	47
T2-weighted Long axis.....	47
T2-weighted Sagittal plane.....	47
Osteophytes .....	48
T1-weighted Long axis.....	48
T1-weighted Sagittal plane.....	48
Effusion-Synovitis .....	49
Short tau inversion recovery Long axis .....	49

T2-weighted Sagittal plane.....	49
Subchondral Cyst.....	50
T2-weighted Long axis.....	50
T1-weighted Sagittal plane.....	50
Bone Marrow Lesion .....	51
T2-weighted & Short tau inversion recovery Long axis.....	51
T2-weighted Sagittal plane.....	51
<b>Fourth Tarso-metatarsal Joint.....</b>	<b>52</b>
Joint Space Narrowing.....	52
T2-weighted Long axis.....	52
T1-weighted Sagittal plane.....	52
Osteophytes .....	53
T1-weighted Long axis.....	53
T1-weighted Sagittal plane.....	53
Effusion-Synovitis.....	54
T2-weighted Long axis.....	54
T2-weighted Sagittal plane.....	54
Subchondral Cyst.....	55
T2-weighted Long axis.....	55
T1-weighted Sagittal plane.....	55
Bone Marrow Lesion .....	56
T2-weighted Long axis.....	56
T2-weighted Sagittal plane.....	56
<b>Fifth Tarso-metatarsal Joint .....</b>	<b>57</b>
Joint Space Narrowing.....	57
T2-weighted Long axis.....	57
T2-weighted Sagittal plane.....	57
Osteophytes .....	58
T1-weighted Long axis.....	58
T1-weighted Sagittal plane.....	58
Effusion-Synovitis.....	59
Short tau inversion recovery Long axis .....	59
T2-weighted Sagittal plane.....	59
Subchondral Cyst.....	60
Short tau inversion recovery Long Axis .....	60
T1-weighted Sagittal plane.....	60
Bone Marrow Lesion .....	61
T2-weighted Long axis.....	61
T2-weighted Sagittal plane.....	61
<b>Tarso-metatarsal Score.....</b>	<b>62</b>
Bone Erosion exemplar .....	62
T1-weighted Long axis.....	62
T1-weighted Sagittal plane.....	62
<b>Tarsal Bone Scores .....</b>	<b>63</b>
Talus Bone Marrow Lesion.....	63
T1-weighted Long axis.....	63
T1-weighted Sagittal plane.....	63
Calcaneus Bone Marrow Lesion .....	64
T2-weighted Sagittal plane.....	64
T1-weighted Sagittal plane.....	64
Navicular Bone Marrow Lesion .....	65
T2-weighted Long axis.....	65
T2-weighted Sagittal plane.....	65
Medial Cuneiform Bone Marrow Lesion .....	66

T2-weighted Long axis .....	66
T2-weighted Sagittal plane.....	66
Intermediate Cuneiform Bone Marrow Lesion .....	67
T2-weighted Long axis .....	67
T2-weighted Sagittal plane.....	67
Lateral Cuneiform Bone Marrow Lesion .....	68
T2-weighted Long axis.....	68
T2-weighted & Short tau inversion recovery Sagittal plane.....	68
Cuboid Bone Marrow Lesion .....	69
T2-weighted Long axis.....	69
T2-weighted Sagittal plane.....	69
<b>Representative Tarsal Bone Score .....</b>	<b>70</b>
Bone Erosion .....	70
Medial Cuneiform.....	70
Intermediate Cuneiform.....	70
Cuboid .....	70
T1-weighted Long axis.....	70
T1-weighted Sagittal plane.....	70
<b>Tarsal Joints.....</b>	<b>71</b>
Talo-calcaneal Joint Space Narrowing.....	71
T2-weighted Sagittal plane.....	71
T1-weighted Sagittal plane.....	71
Talo-calcaneal Osteophytes .....	72
T2-weighted Sagittal plane.....	72
T1-weighted Sagittal plane.....	72
Talo-calcaneal Effusion-Synovitis .....	73
T2-weighted Sagittal plane.....	73
T1-weighted Sagittal plane.....	73
Talo-calcaneal Subchondral Cyst.....	74
T2-weighted Sagittal plane.....	74
T1-weighted Sagittal plane.....	74
Talo-navicular Joint Space Narrowing.....	75
T2-weighted Sagittal plane.....	75
T1-weighted Sagittal plane.....	75
Talo-navicular Osteophytes.....	76
T1-weighted Long axis.....	76
T1-weighted Sagittal plane.....	76
Talo-navicular Effusion-Synovitis .....	77
T2-weighted Long axis.....	77
T2-weighted Sagittal plane.....	77
Talo-navicular Subchondral Cyst .....	78
T2-weighted Long axis.....	78
T2-weighted Sagittal plane.....	78
T1-weighted Sagittal plane.....	78
Calcaneo-cuboid Joint Space Narrowing.....	79
T2-weighted Long axis.....	79
T2-weighted Sagittal plane.....	79
T1-weighted Sagittal plane.....	79
Calcaneo-cuboid Osteophytes .....	80
T1-weighted Long axis.....	80
T1-weighted Sagittal plane.....	80
Calcaneo-cuboid Effusion-Synovitis .....	81
T2-weighted Long axis.....	81
T2-weighted Sagittal plane.....	81

Calcaneo-cuboid Subchondral Cyst.....	82
T2-weighted Long Axis .....	82
T2-weighted Sagittal plane.....	82
T1-weighted Sagittal plane.....	82
Naviculo-medial Cuneiform Joint Space Narrowing.....	83
T2-weighted Long axis.....	83
T1-weighted Sagittal plane.....	83
Naviculo-medial Cuneiform Osteophytes .....	84
T1-weighted Long axis.....	84
T1-weighted Sagittal plane.....	84
Naviculo-medial Cuneiform Effusion-Synovitis.....	85
T2-weighted Long axis.....	85
T2-weighted Sagittal plane.....	85
Naviculo-medial Cuneiform Subchondral Cyst.....	86
T2-weighted Long axis.....	86
T2-weighted Sagittal plane.....	86
T1-weighted Sagittal plane.....	86
Naviculo-intermediate Cuneiform Joint Space Narrowing .....	87
T2-weighted Long axis.....	87
T1-weighted Sagittal plane.....	87
Naviculo-intermediate Cuneiform Osteophytes .....	88
T1-weighted Long axis.....	88
T1-weighted Sagittal plane.....	88
Naviculo-intermediate Cuneiform Effusion-Synovitis.....	89
T2-weighted Long axis.....	89
T2-weighted Sagittal plane.....	89
Naviculo-intermediate Cuneiform Subchondral Cyst .....	90
T2-weighted Long axis.....	90
T2-weighted Sagittal plane.....	90
T1-weighted Sagittal plane.....	90
Naviculo-lateral Cuneiform Joint Space Narrowing .....	91
T2-weighted Long axis.....	91
T1-weighted Sagittal plane.....	91
Naviculo-lateral Cuneiform Osteophytes.....	92
T1-weighted Long axis.....	92
T1-weighted Sagittal plane.....	92
Naviculo-lateral Cuneiform Effusion-Synovitis.....	93
T2-weighted Long axis.....	93
T2-weighted Sagittal plane.....	93
Naviculo-lateral Cuneiform Subchondral Cyst .....	94
T2-weighted Long axis.....	94
T2-weighted Sagittal plane.....	94
T1-weighted Sagittal plane.....	94
<b>Chapter 4. Soft Tissue .....</b>	<b>95</b>
<b>Ligament Abnormality Scores.....</b>	<b>96</b>
Lisfranc (1a and 1b) and Intertarsal ligaments (2a and 2b) .....	96
T2-weighted Long axis.....	96
T2-weighted Short axis.....	96
<b>Tenosynovitis .....</b>	<b>97</b>
Tibialis Anterior .....	97
T2-weighted Sagittal plane.....	97
T2-weighted Short axis.....	97
Extensor Hallucis Longus .....	98
T2-weighted Sagittal plane.....	98

T2-weighted Short axis .....	98
Extensor Digitorum Longus .....	99
T2-weighted Sagittal plane.....	99
T2-weighted Short axis .....	99
Peroneus Brevis.....	100
T2-weighted Sagittal plane.....	100
T2-weighted Short axis.....	100
Peroneus Longus .....	101
T2-weighted Sagittal plane.....	101
T2-weighted Short axis .....	101
Tibialis Posterior.....	102
T2-weighted Sagittal plane.....	102
T2-weighted Short axis .....	102
Flexor Digitorum Longus .....	103
T2-weighted Sagittal plane.....	103
T2-weighted Short axis .....	103
Flexor Hallucis Longus .....	104
T2-weighted Sagittal plane.....	104
T2-weighted Short axis .....	104
<b>Enthesopathy Scores .....</b>	<b>105</b>
Tibialis Anterior 1st Metatarsal (1a) and Medial Cuneiform (1b) .....	105
T2-weighted Sagittal plane.....	105
T2-weighted Short axis .....	105
Peroneus Longus 1st Metatarsal (1a) and Medial Cuneiform (1b) .....	106
T2-weighted Sagittal plane.....	106
T2-weighted Short axis.....	106
Peroneus Brevis Base of 5th Metatarsal .....	107
T2-weighted Sagittal plane.....	107
T2-weighted Short axis .....	107
Tibialis Posterior Medial Cuneiform (1a) and 2/3/4 Metatarsal (1b) .....	108
T2-weighted Sagittal plane.....	108
T2-weighted Short axis .....	108
Tibialis Posterior Navicular (1c) and Lateral Cuneiform (1d) .....	109
T2-weighted Sagittal plane.....	109
T2-weighted Short axis .....	109
<b>Sub Tendon Bone Marrow Lesion (Tendon Groove).....</b>	<b>110</b>
Tibialis Posterior Navicular (1a) Medial Cuneiform (1b) .....	110
T2-weighted Sagittal plane.....	110
T2-weighted Short axis .....	110
Peroneus Longus Cuboid (1a) and Lateral Cuneiform (1b) .....	111
T2-weighted Sagittal plane.....	111
T2-weighted Short axis .....	111
Tibialis Anterior Medial Cuneiform .....	112
T2-weighted Sagittal plane.....	112
T2-weighted Short axis.....	112



## **Chapter 1. Definitions and Score sheet**

<b>Definitions</b> Anatomical location and description	<b>Definition of the feature</b>	<b>Score</b>
Joint space narrowing (JSN) All the joints of the hindfoot, tarsus, midfoot and metatarsophalangeal joints.	Increased signal in T2-weighted images (fat suppressed or inversion recovery sequences) and or loss of joint space as a partial or complete loss on T1-weighted images. Visible in two planes.	JSN was scored as 0 to 3: 0 = Normal thickness and signal 1 = Increased signal 2 = Partial-thickness focal loss 3 = Full thickness loss of joint space (>=75% of the region)
Osteophytes All of the joints of the hindfoot, tarsus, midfoot and metatarsophalangeal joints	Abnormal bone formation in the periarticular region on T1-weighted images. Visible in two planes.	Osteophytes were scored as 0 to 3: 0 = None, 1 = Mild, 2 = Moderate, 3 = Large
Effusion-synovitis All of the joints of the hindfoot, tarsus, midfoot and metatarsophalangeal joints	The presence of increased intra articular fluid, demonstrated as high signal intensity on T2-weighted images (fat suppressed or inversion recovery sequences). Visible in two planes.	Effusion-synovitis was scored as 0 to 1: 0 = Absent and 1 = Present
Subchondral cyst All of the joints of the hindfoot, tarsus, midfoot and metatarsophalangeal joints	A sharply marginated subchondral bone lesion that showed increased signal intensity on T2-weighted images (fat suppressed or inversion recovery sequences). Visible in two planes, without a cortical break.	Cysts were scored as 0 to 1: 0 = Absent and 1 = Present

<p>Bone marrow lesion (BML) All bones of the hindfoot, tarsus, midfoot and metatarsals.</p>	<p>An area of ill delineated signal within the trabecular bone that shows decreased signal intensity on T1-weighted images and increased signal intensity on T2-weighted images (fat suppressed or inversion recovery sequences). Visible in at least in two planes.</p>	<p>BML was scored as 0 to 3, according to the proportion of bone with abnormal signal: 0 = None, 1 = 1%–33%, 2 = 34%–66%, 3 = 67%–100%</p> <p>Except in the Long Axis bones of the metatarsals, where the BML was scored in three regions per bone:</p> <p>(i) At the proximal joint, the base (up to the epiphysis and metaphysis) was included in the tarsometatarsal and scored 0 to 3.</p> <p>(ii) At the central region, metatarsal shaft (diaphysis) was divided into proximal, central and distal in one third increments (33%) on a bone level and scored 0 to 3.</p> <p>(iii) At the distal region the head (to the epiphysis and metaphysis) was included in the metatarsophalangeal joint and scored 0 to 3.</p>
<p>Bone erosion All bones of the hindfoot, tarsus, midfoot and metatarsals.</p>	<p>A bone defect in the cortical and juxta-cortical region, with sharp margins visible on T1-weighted images and with a loss of normal low signal intensity of cortical bone and loss of normal high signal intensity of marrow fat. Visible in two planes with a cortical break seen in at least one plane.</p>	<p>Erosions were scored from 0 to 3: according to the volume of the erosion as a proportion of the joint margin:</p> <p>0 = No erosion 1 = 1%–33% 2 = 34%–66% 3 = 67%–100%</p>

<p>Enthesopathy Locations at the insertion of the tendons: posterior tibial, anterior tibial, flexor digitorum, flexor hallucis, extensor digitorum, extensor hallucis, peroneus longus and peroneus brevis; Sites at the attachments of the Lisfranc and intertarsal ligament complex.</p>	<p>A bone marrow lesion pattern, where altered signal intensity within the bone was adjacent to insertions of anatomically defined ligaments and/or tendons of the foot. Shown as increased signal intensity on T2-weighted sequences and decreased signal intensity on T1-weighted images. Visible in at least two planes.</p>	<p>Enthesopathy scored as 0 to 1: 0 = Absent and 1 = Present</p>
<p>Sub-tendon Bone Marrow Lesion (BML) (also known as functional enthesopathy) Bones of the hindfoot, tarsus, midfoot and metatarsals adjacent to the course of a tendon at the medial (posterior tibial, and anterior tibial tendons), lateral (peroneus longus and peroneus brevis), plantar (flexor digitorum and flexor hallucis longus tendons) and dorsal (extensor digitorum and extensor hallucis longus tendons) regions.</p>	<p>A bone marrow lesion pattern where increased signal intensity within the bone was adjacent to the course of a tendon and away from an articular surface. Shown as increased signal intensity on T2-weighted sequences and decreased signal intensity on T1-weighted images. Visible in at least two planes.</p>	<p>Sub-tendon BML was scored as 0 to 1: 0 = Absent and 1 = Present</p>
<p>Tenosynovitis Tendon locations: Posterior tibial, anterior tibial, flexor digitorum, flexor hallucis, extensor digitorum, extensor hallucis, peroneus longus and peroneus brevis</p>	<p>Decreased signal intensity on T1-weighted images and increased signal on T2-weighted images (fat suppressed or inversion recovery sequences) in a region of the tendon with an enclosing tendon sheath. Visible in at least two planes.</p>	<p>Tenosynovitis was scored 0 to 3: 0 = Normal 1 = &lt;2 mm peritendinous effusion. 2 = &gt;2 and ≤5 mm peritendinous effusion and/or thickening and high intra-tendinous signal intensity 3 = &gt;5 mm peritendinous effusion and/or higher thickening and high intra-tendinous signal intensity.</p>


Ligament abnormality Ligament locations: Lisfranc and inter-tarsal ligament complex.	Thickening and high signal intensity identified on T2-weighted images (fat suppressed or inversion recovery sequences) with or without disruption. Visible in at least two planes: axial and coronal.	Ligament abnormality was scored 0 to 1: 0 = Absent and 1 = Present
---	---	---

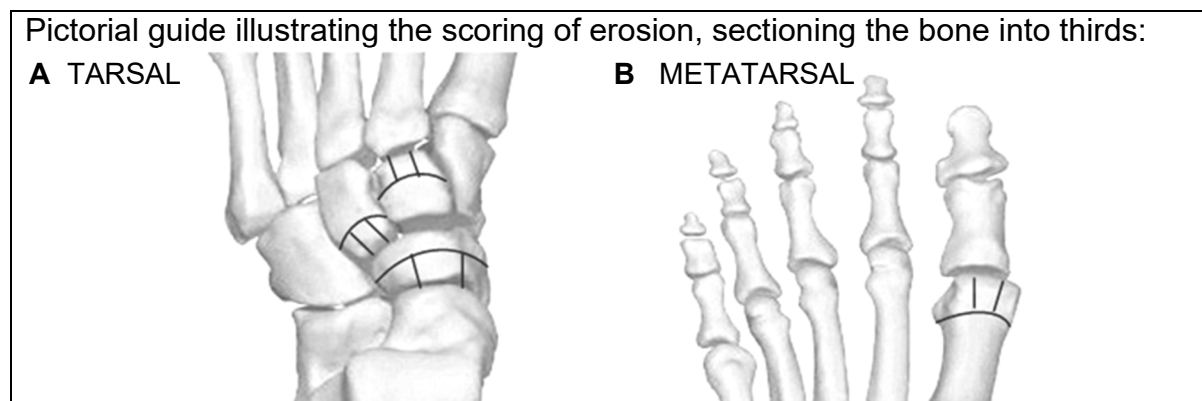
### Foot Osteoarthritis MRI Score Sheet

MRI ID \_\_\_\_\_

Sequences \_\_\_\_\_

Forefoot		Metatarso-phalangeal Joint Scores				
Features		1st	2 <sup>nd</sup>	3rd	4th	5th
Joint space narrowing (score 0-3)						
Osteophytosis (score 0-3)						
Effusion (score 0-1)						
Subchondral cysts (score 0-1)						
Bone marrow lesion (score 0-3)	Proximal Metatarsal head					
	Distal Phalanx base					
Bone erosion (Score 0-3)	Proximal Metatarsal head					
	Distal Phalanx base					
Comments : FOV / positioning issues						

	Forefoot		Metatarsal Bone Scores				
	Features		1st	2nd	3rd	4th	5th
 <p>Bone marrow lesion (score 0-3) Illustration of bone shaft divided into proximal, central and distal regions of the shaft</p>	Proximal Shaft						
	Central Shaft						
	Distal Shaft						



Midfoot	Tarso-metatarsal Joint Scores				
Features	1st	2nd	3rd	4th	5th
<b>Joint space narrowing</b> (score 0-3)					
<b>Osteophytosis</b> (score 0-3)					
<b>Effusion</b> (score 0-1)					
<b>Subchondral cysts</b> (score 0-1)					
<b>Bone marrow lesion</b> <b>Distal - base metatarsal</b> (score 0-3)					
<b>Bone erosion</b> <b>Distal - base metatarsal</b> (score 0-3)					
<b>Ligament</b> (score 0-1 & location)					

Midfoot Bones	Tarsal Bone Scores						
Features	Talus	Calcaneus	Navicular	Medial cuneiform	Intermediate cuneiform	Lateral cuneiform	Cuboid
<b>Bone erosion</b> (score 0-3)							
<b>Bone marrow lesion</b> (score 0-3)							
<b>Comments</b> (e.g. ossicle)							

Foot Osteoarthritis MRI Score Atlas

Midfoot to Hindfoot	Tarsal and Hindfoot Joint Scores						
	Tibio-talar joint	Talo-calcaneal joint	Talo-navicular joint	Calcaneo-cuboid joint	Naviculo-cuneiform joints*		
Features					Medial	Interm**	Lateral
<b>Joint space narrowing</b> (score 0-3)							
<b>Osteophytosis</b> (score 0-3)							
<b>Effusion</b> (score 0-1)							
<b>Subchondral cysts</b> (score 0-1)							
<b>Ligament</b> (score 0-1 & location)							

\* This can be scored as one continuous joint or individual joints

\*\* Interm = Intermediate

Soft Tissue Tenosynovitis	Score (0-3)
<b>Tibialis Anterior</b>	
<b>Extensor Hallucis Longus</b>	
<b>Extensor Digitorum Longus</b>	
<b>Peroneus Brevis</b>	
<b>Peroneus Longus</b>	
<b>Tibialis Posterior</b>	
<b>Flexor Digitorum Longus</b>	
<b>Flexor Hallucis Longus</b>	

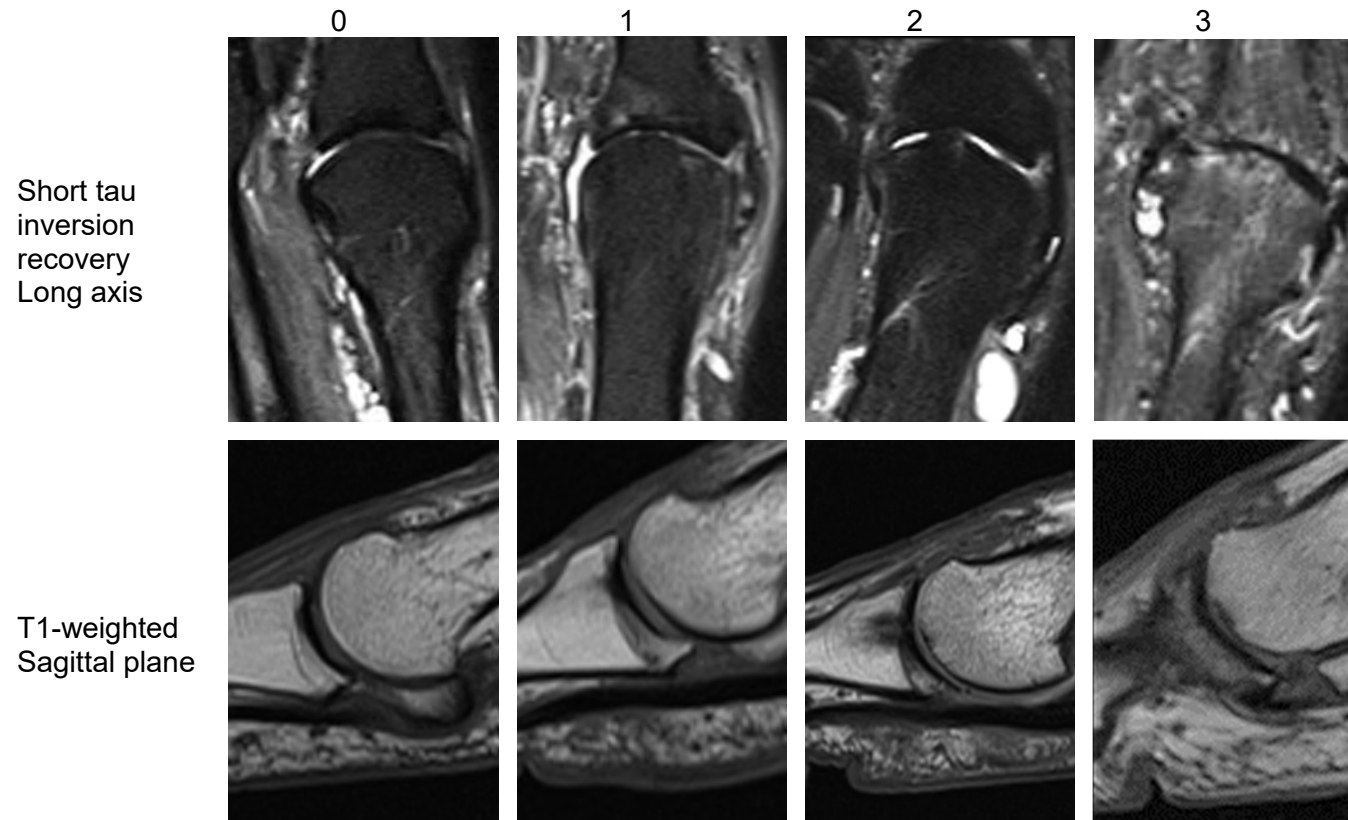


Enthesopathy Score (bone marrow lesion located at enthesis of tendon)									
Feature	Location								
<b>Bone location</b>	<b>1<sup>st</sup> Metatarsal</b> <i>Plantar medial</i>	<b>1<sup>st</sup> Metatarsal</b> <i>Plantar lateral</i>	<b>2nd, 3rd, 4th Metatarsal</b> <i>Plantar</i>	<b>Base 5<sup>th</sup> Metatarsal</b> <i>Proximal dorsal-lateral</i>	<b>Medial cuneiform</b> <i>Plantar distal-medial</i>	<b>Medial cuneiform</b> <i>Plantar distal-lateral</i>	<b>Medial cuneiform</b> <i>Plantar proximal</i>	<b>Lateral cuneiform</b> <i>Plantar medial</i>	<b>Navicular</b> <i>Plantar medial</i>
<b>Tendon</b>	<b>Tibialis Anterior</b>	<b>Peroneus Longus</b>	<b>Tibialis Posterior</b>	<b>Peroneus Brevis</b>	<b>Tibialis Anterior</b>	<b>Peroneus longus</b>	<b>Tibialis Posterior</b>	<b>Tibialis Posterior</b>	<b>Tibialis Posterior</b>
<b>Bone signal</b> (score 0-1)									

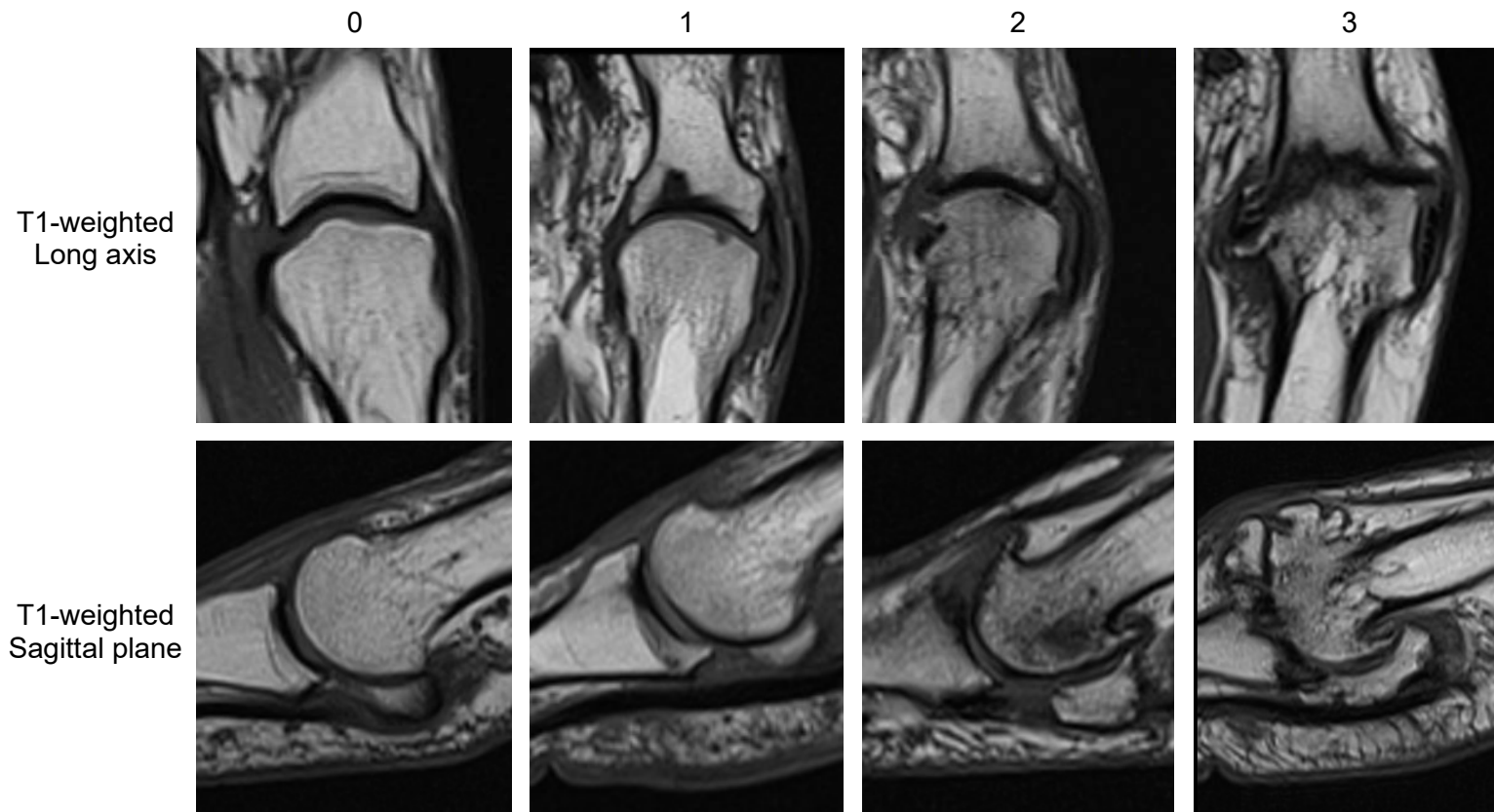
Sub-tendon bone marrow lesion score					
Feature	Location of sub-tendon at bone and tendon groove				
<b>Bone location</b>	<b>Medial Calcaneus</b>	<b>Lateral Calcaneus</b>	<b>Navicular</b>	<b>Medial cuneiform</b>	<b>Cuboid</b>
<b>Tendon</b>	<b>Tibialis Posterior</b>	<b>Peroneus Longus</b>	<b>Tibialis Posterior</b>	<b>Tibialis Anterior</b>	<b>Peroneus Longus</b>
<b>Bone signal</b> (score 0-1)					

## **Chapter 2. Forefoot**

First Metatarso-phalangeal Joint  
Joint Space Narrowing



First Metatarso-phalangeal Joint  
Osteophytes

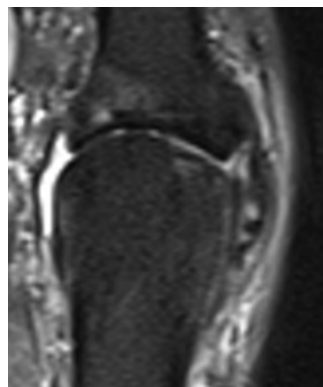
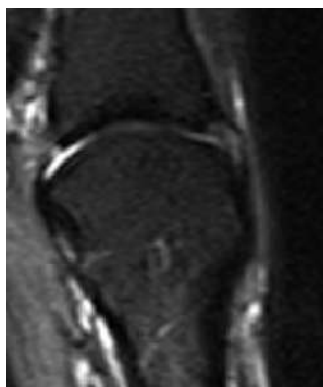

First Metatarso-phalangeal Joint  
Effusion-Synovitis

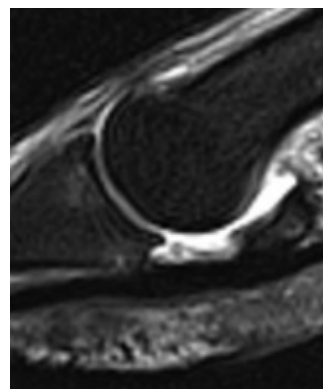
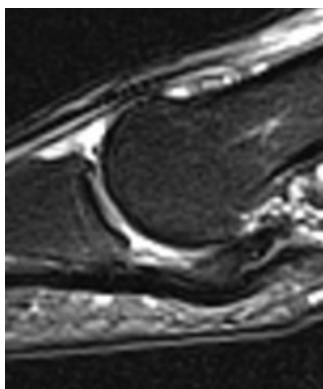
0

1

Short tau  
inversion  
recovery  
Long axis



T2-weighted  
Sagittal plane



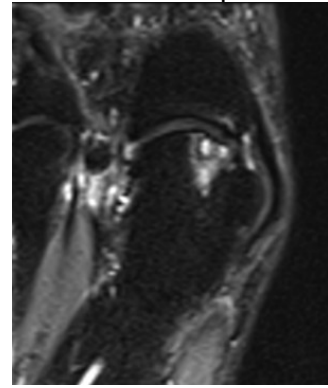
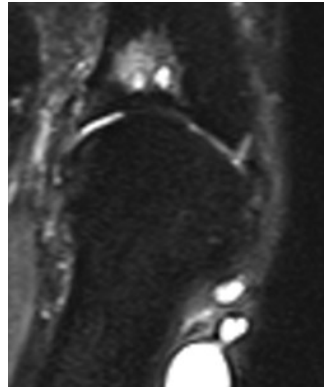
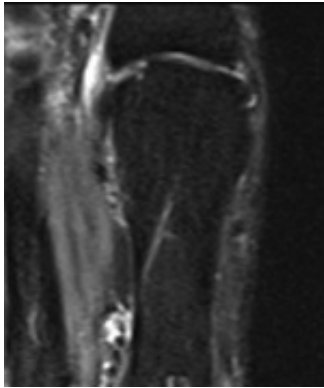
### First Metatarso-phalangeal Joint Subchondral Cyst

0

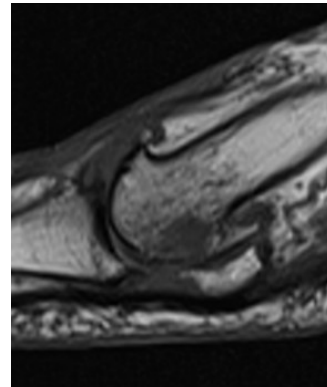
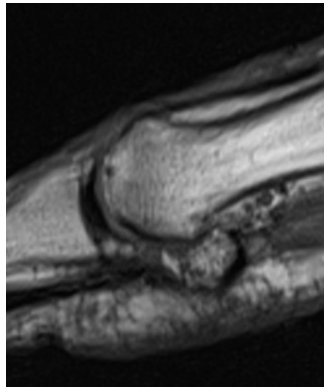
1 distal

1 proximal

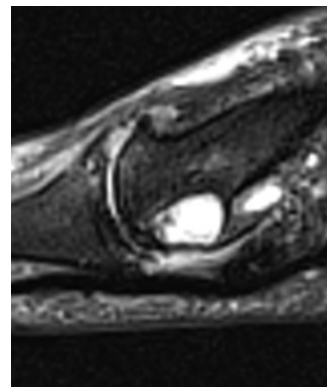
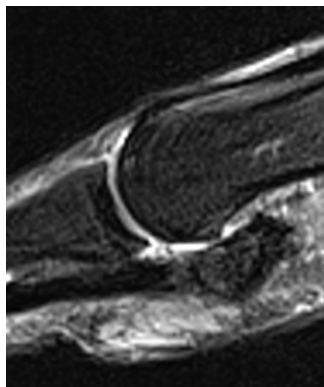
Short tau  
inversion  
recovery  
Long axis



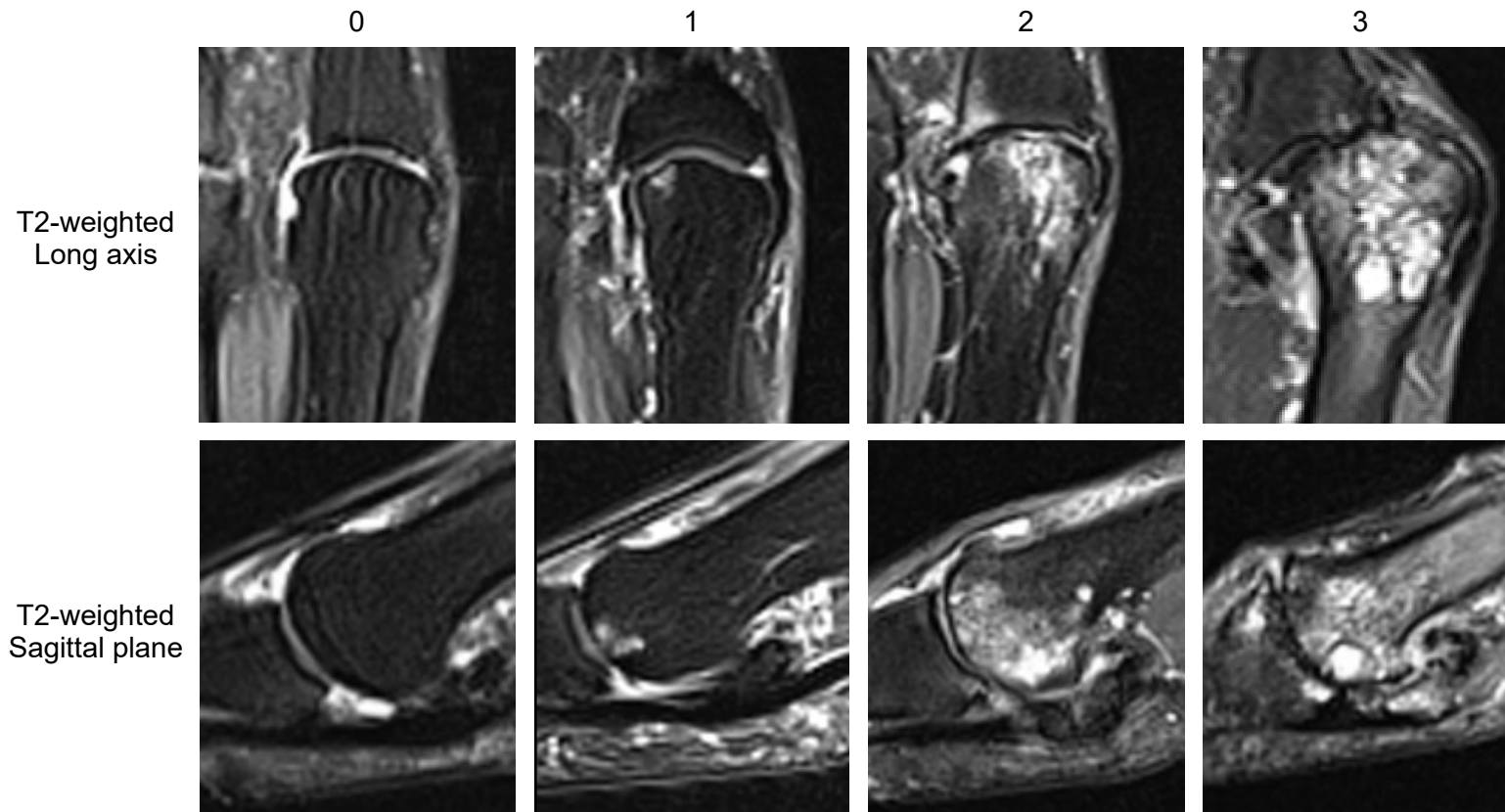
T1-weighted  
Sagittal plane



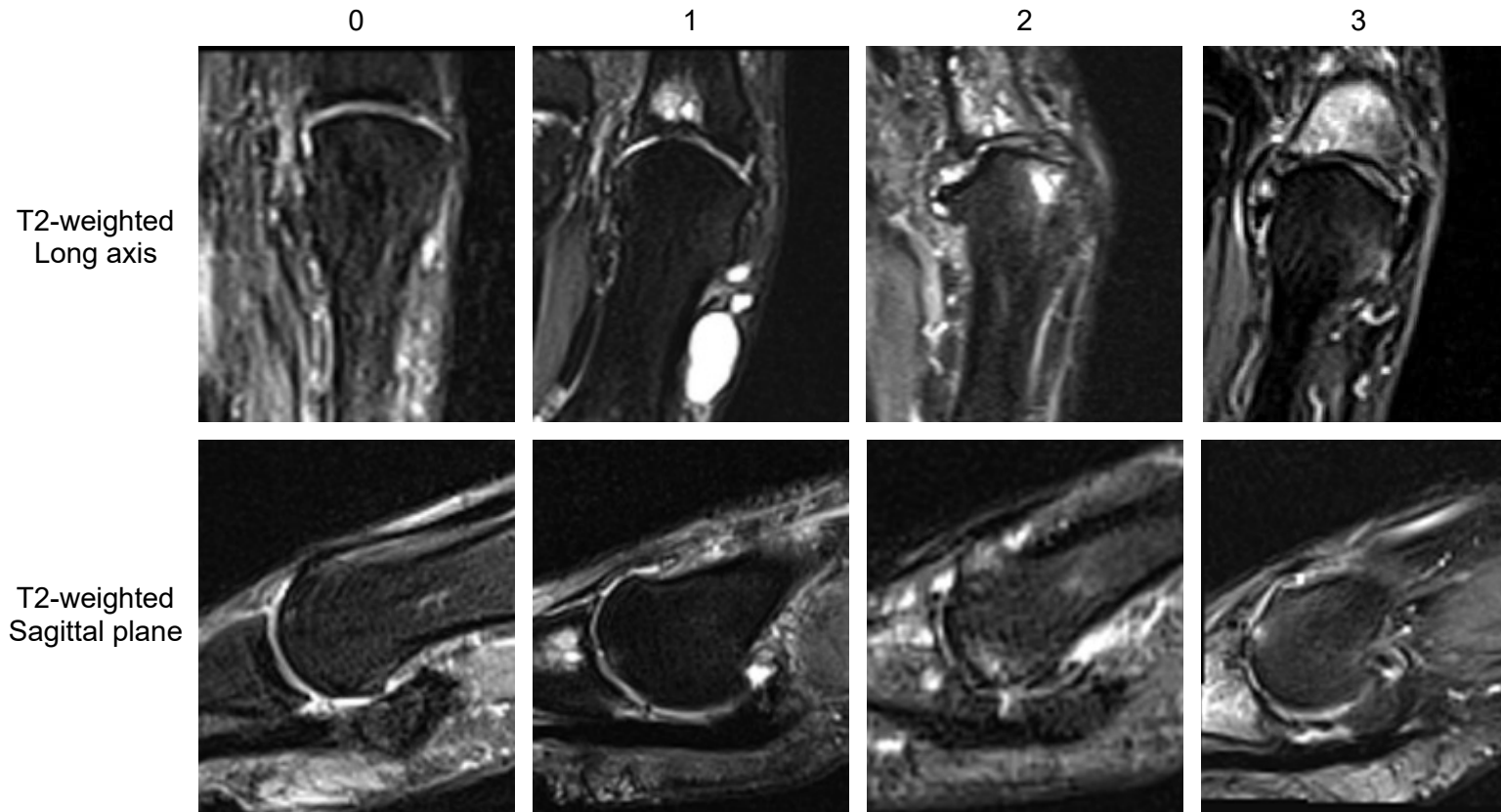
T2-weighted  
Sagittal plane



First Metatarso-phalangeal Joint  
Bone Marrow Lesion Metatarsal Head

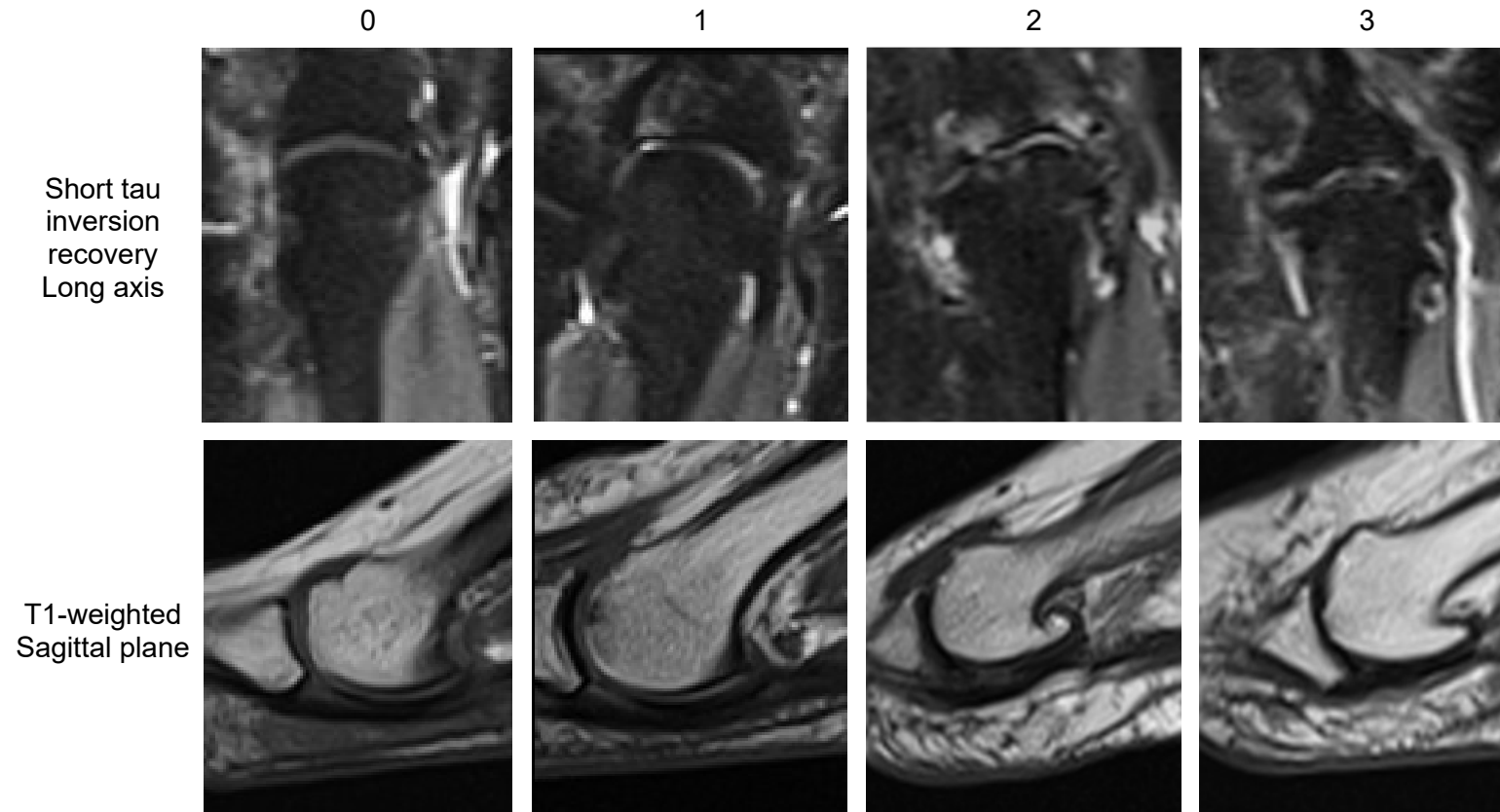


First Metatarso-phalangeal Joint  
Bone Marrow Lesion Phalanx Base

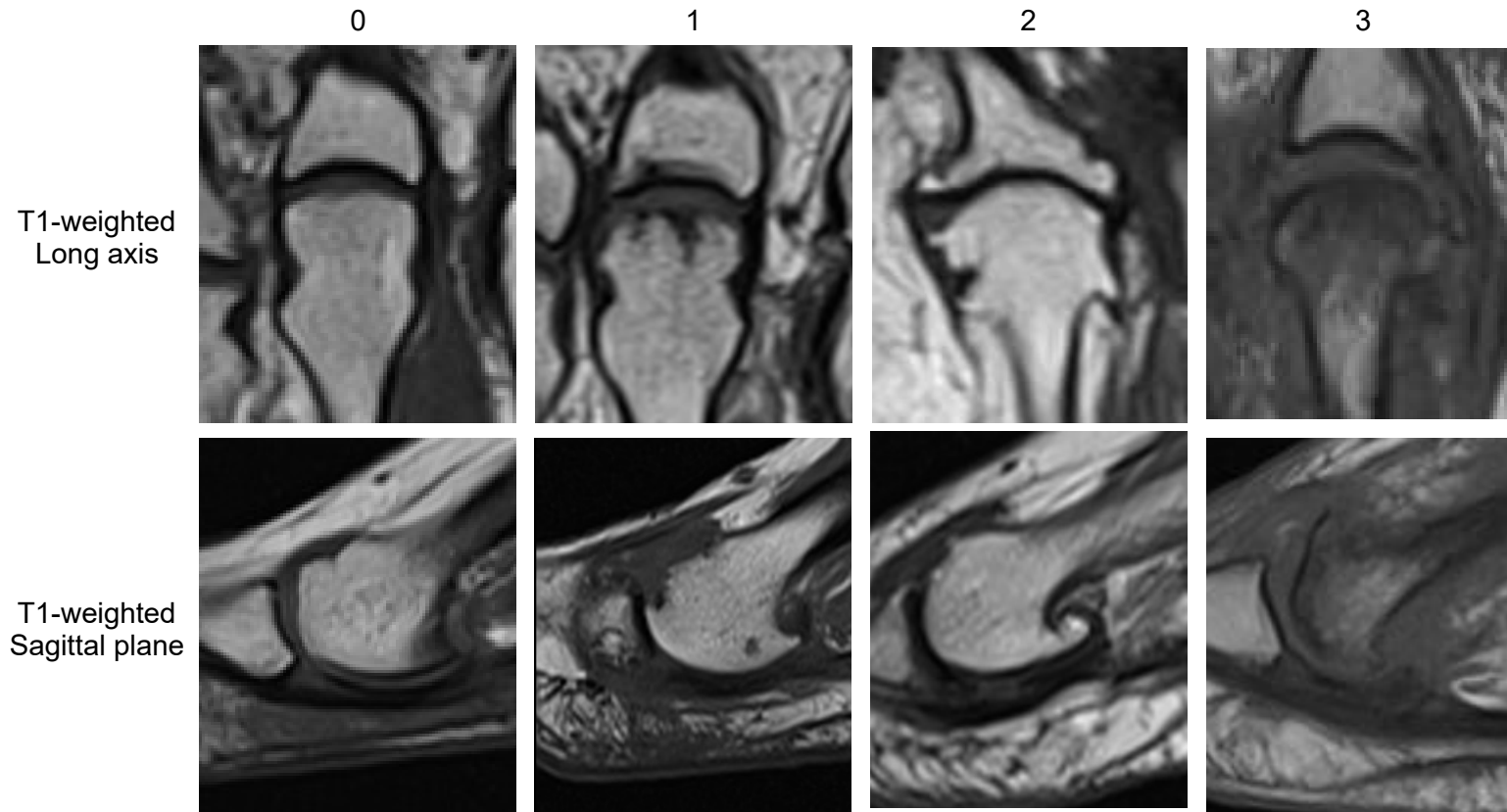




Representative Lesser Toe Metatarso-phalangeal Joint  
Joint Space Narrowing



Representative Lesser Toe Metatarso-phalangeal Joint  
Osteophytes



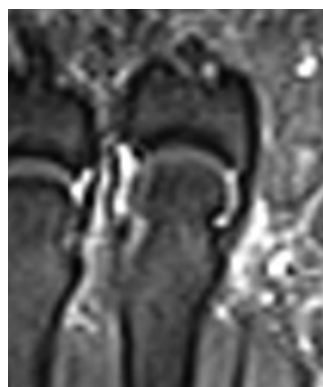
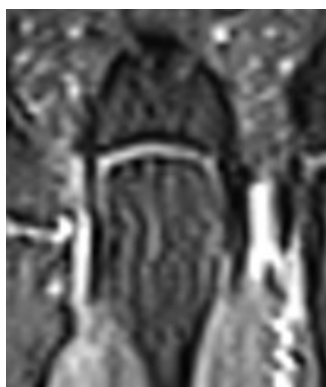
Foot Osteoarthritis MRI Score Atlas

Representative Lesser Toe Metatarso-phalangeal Joint  
Effusion-Synovitis

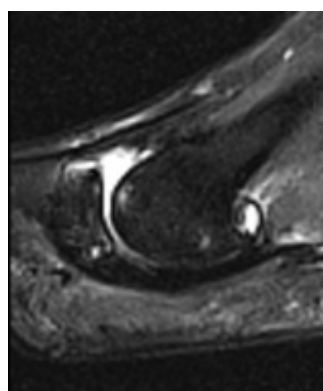
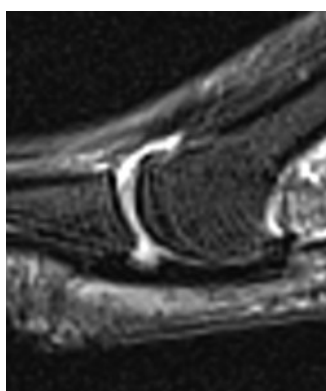
0

1

T2-weighted  
Long axis



T2-weighted  
Sagittal plane

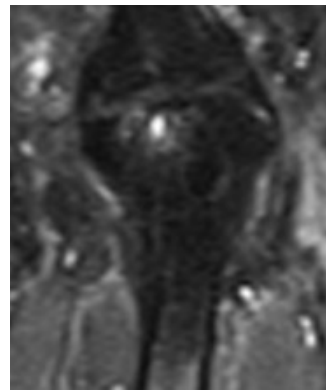
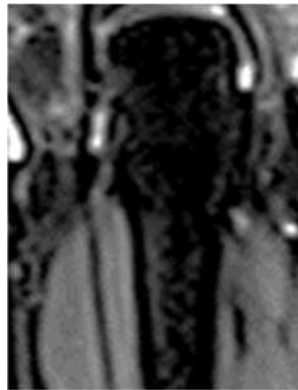

Representative Lesser Toe Metatarso-phalangeal Joint  
Subchondral Cyst

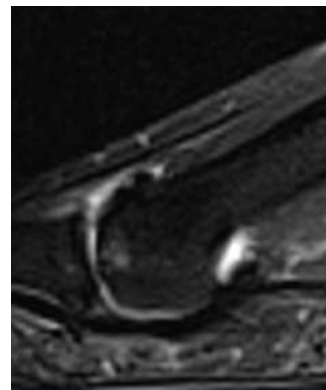
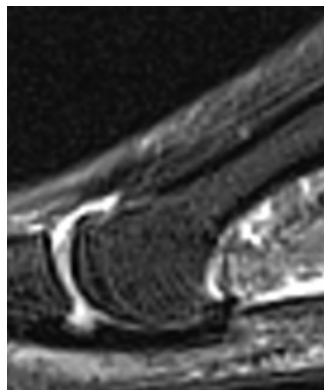
0

1

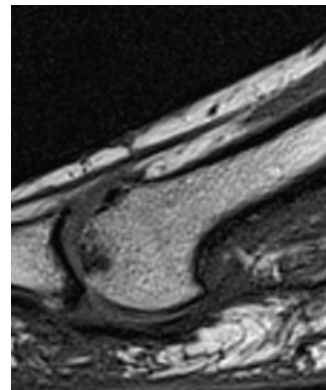
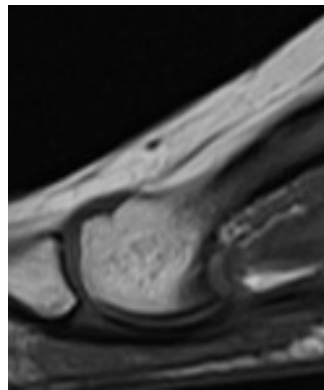
Short tau inversion  
recovery  
Long axis



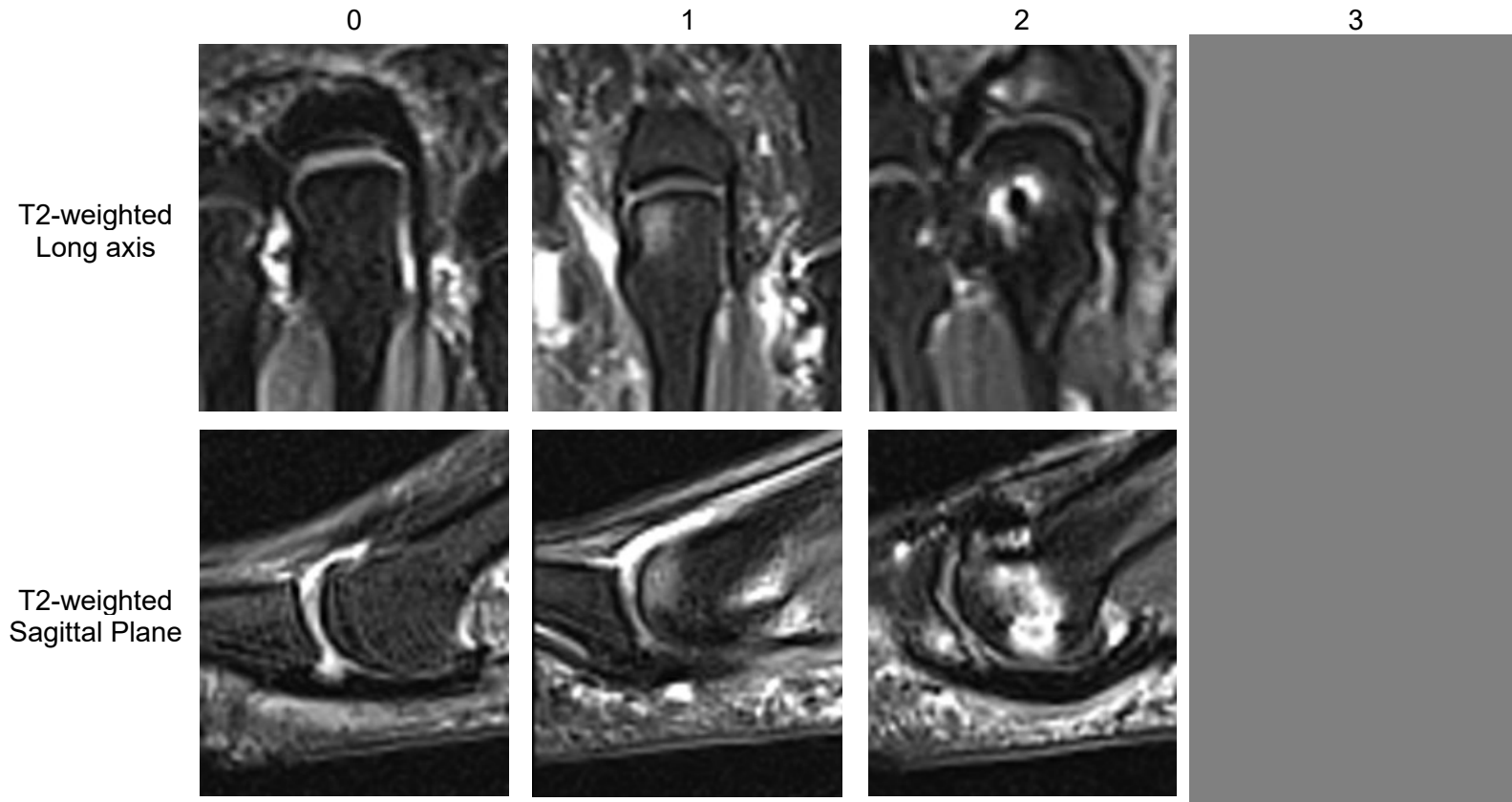
T2-weighted  
Sagittal plane



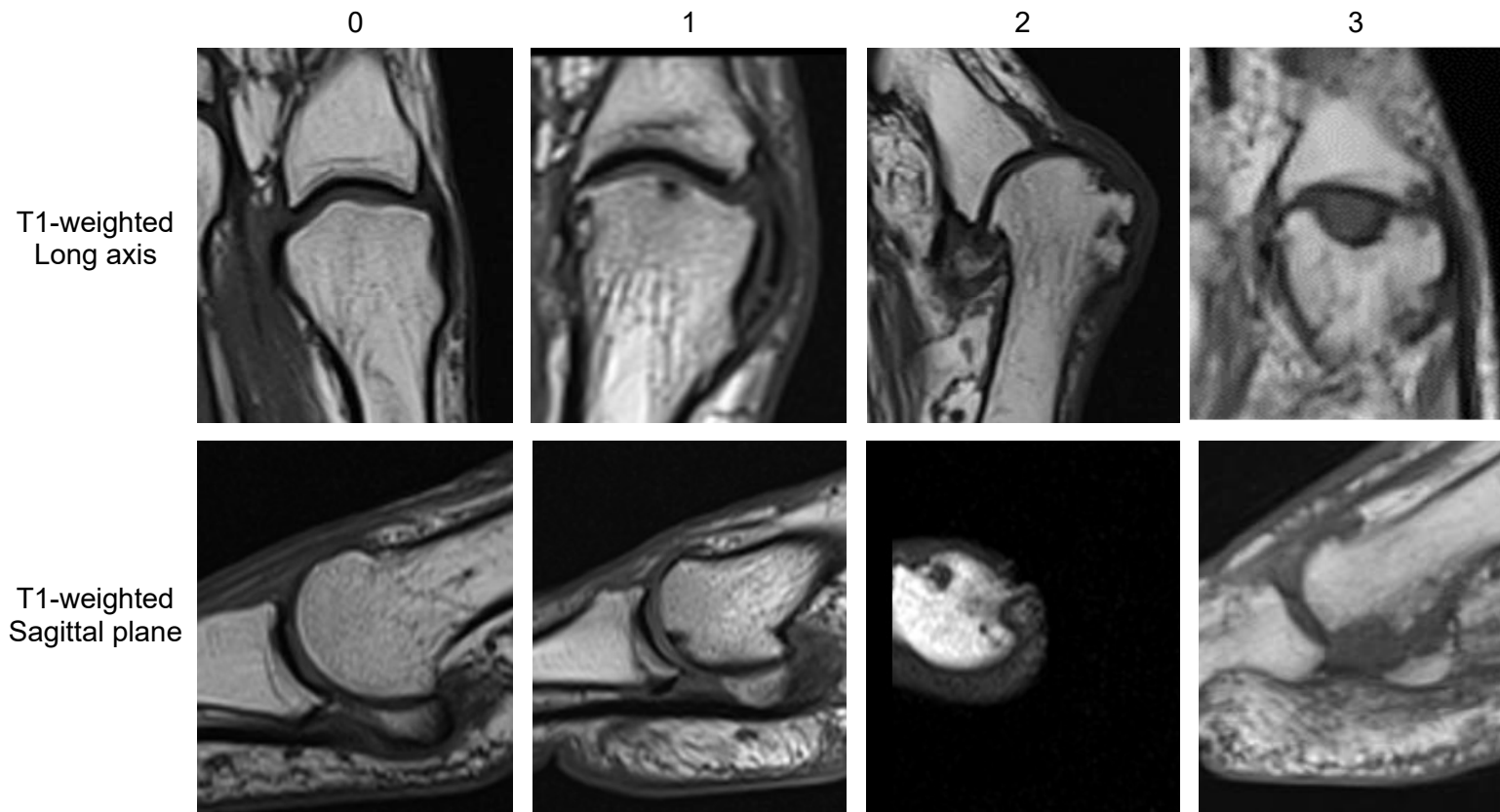
T1-weighted  
Sagittal plane



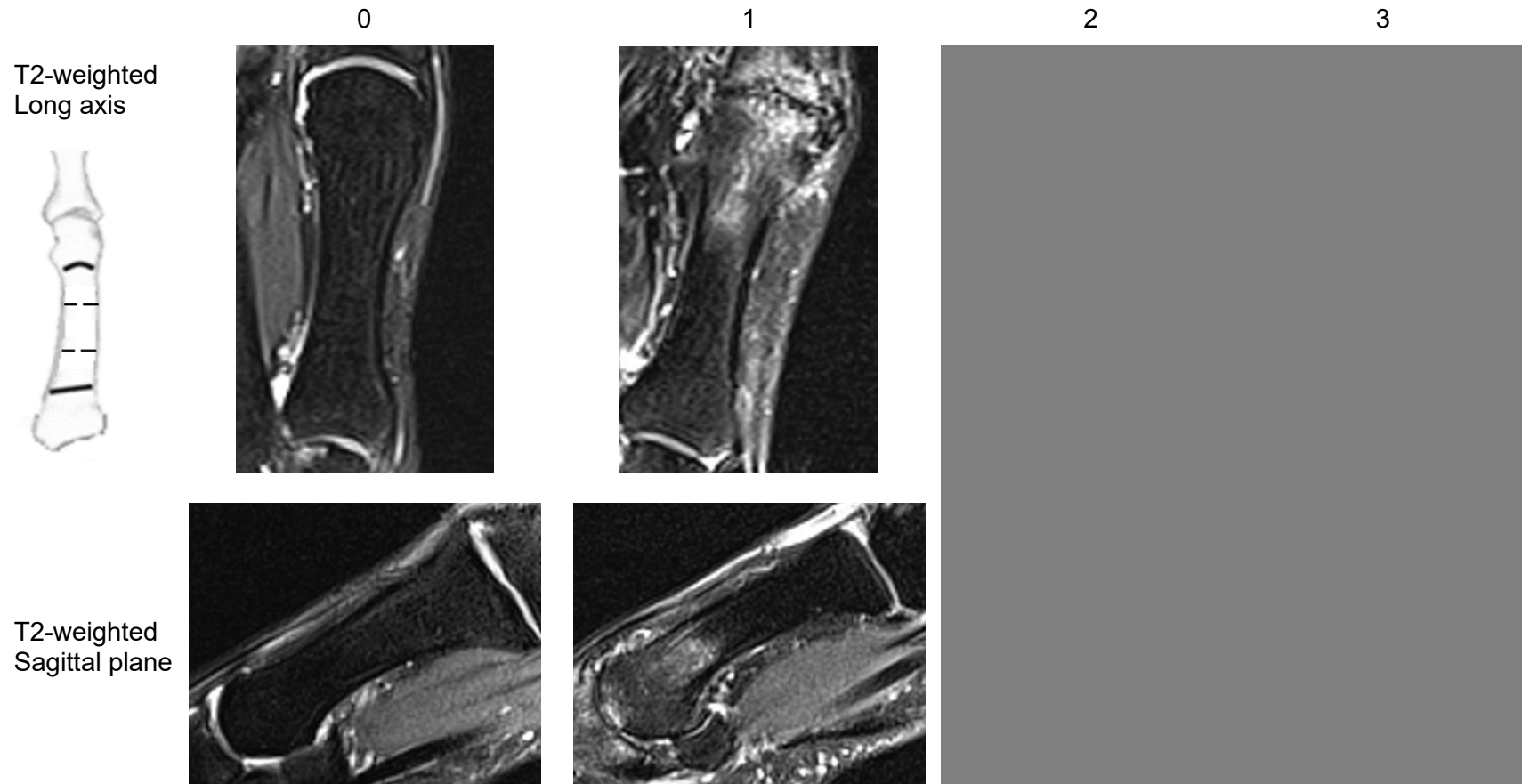
Representative Lesser Toe Metatarso-phalangeal Joint  
Bone Marrow Lesion at Metatarsal Head and or Phalanx Base



Representative Metatarsal Bone Score  
Bone Erosion at Metatarsal Head and or Phalanx Base



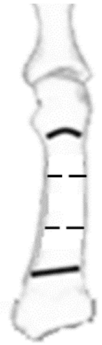
Representative Metatarsal Bone Score  
Bone Marrow Lesion at Distal Shaft Bone



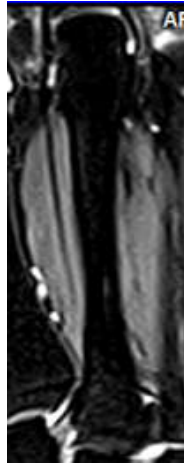


Representative Metatarsal Bone Score  
Bone Marrow Lesion at Central Shaft Bone

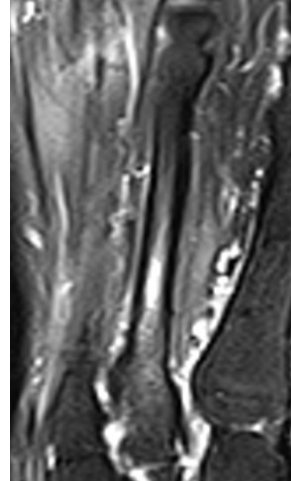
T2-weighted  
Long axis



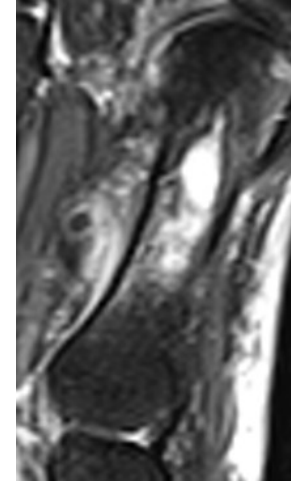
0




1



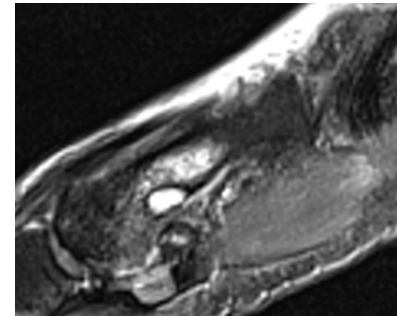
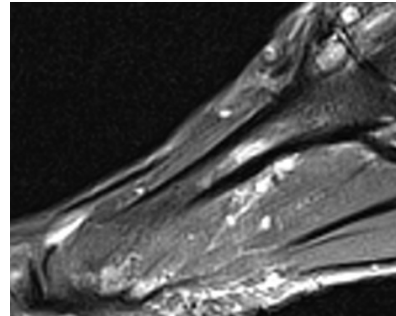
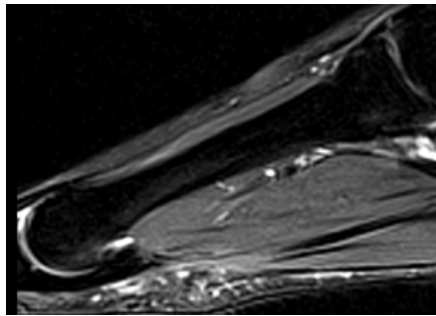
2



3



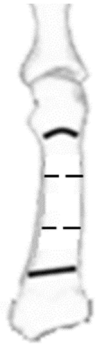
T2-weighted  
Sagittal plane



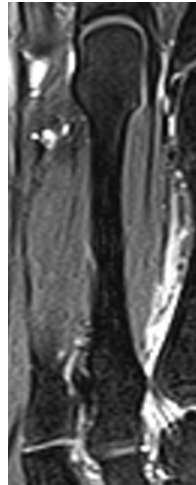


Representative Metatarsal Bone Score  
Bone Marrow Lesion at Proximal Shaft Bone

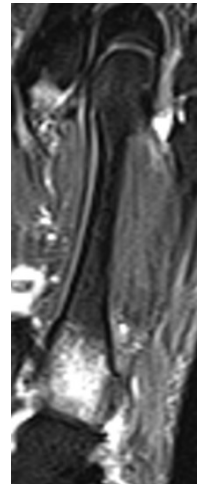
T2-weighted  
Long axis



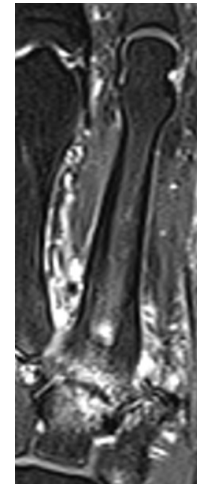
0




1



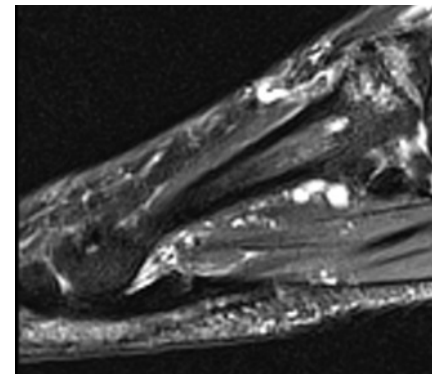
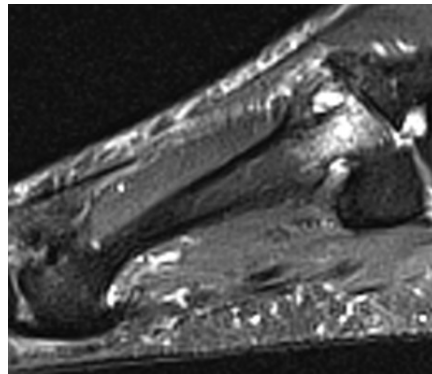
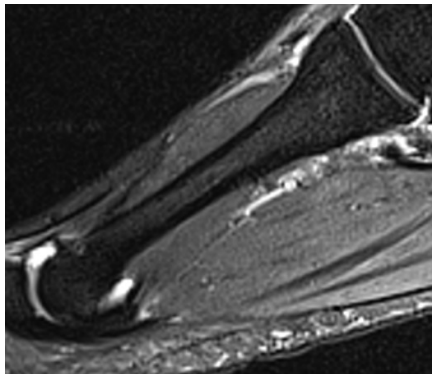
2



3



T2-weighted  
Sagittal plane



## Chapter 3. Midfoot and Hindfoot

First Tarso-metatarsal Joint  
Joint Space Narrowing

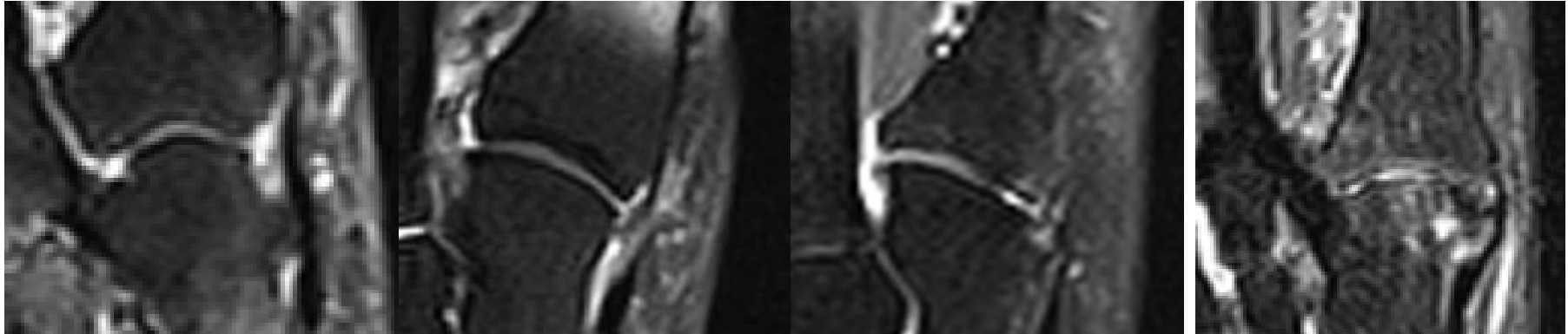
0

1

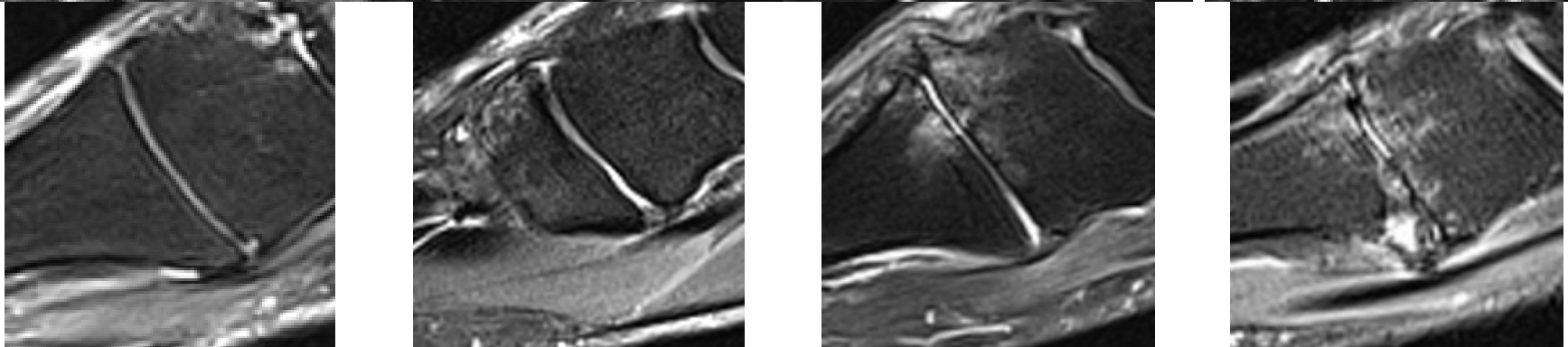
2

3

T2-weighted  
Long axis



T2-weighted  
Sagittal plane



First Tarso-metatarsal Joint  
Osteophytes

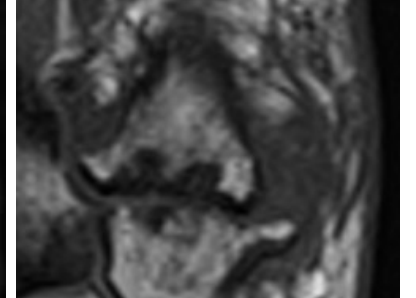
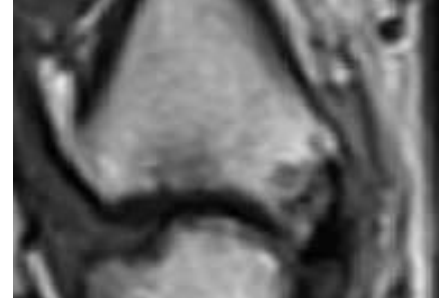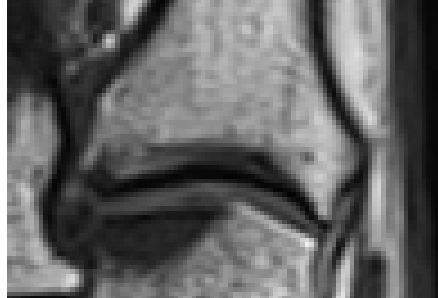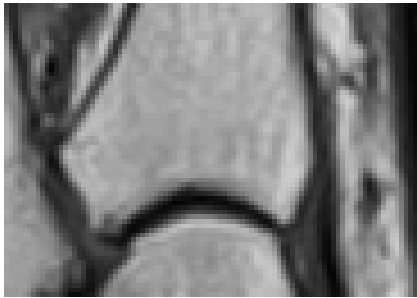
0

1

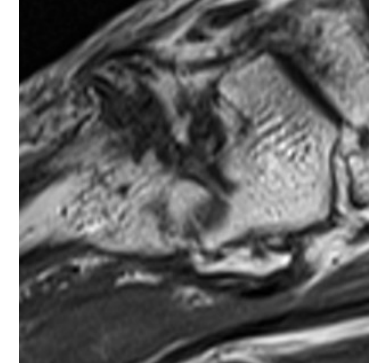
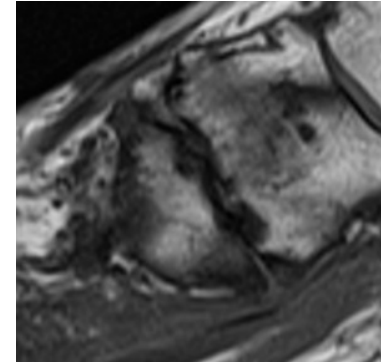
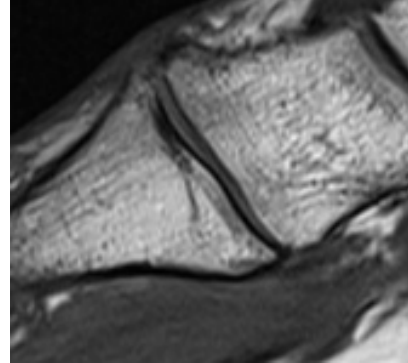
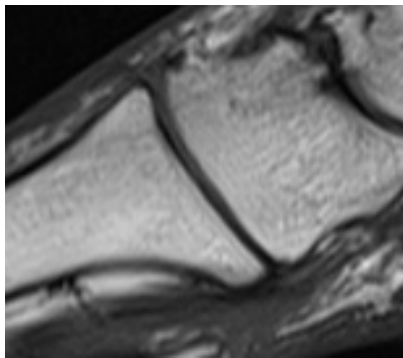
2

3

T1-weighted  
Sagittal plane



T1-weighted  
Long axis

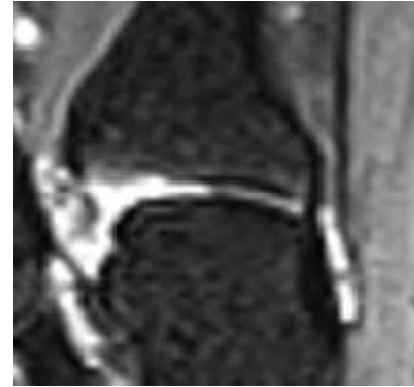
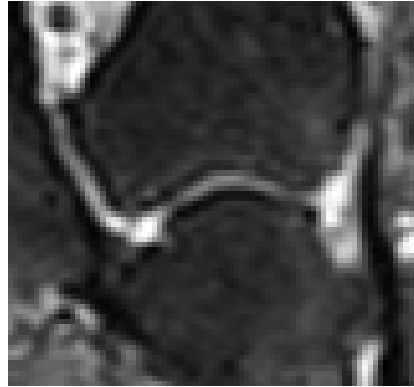


First Tarso-metatarsal Joint  
Effusion-Synovitis

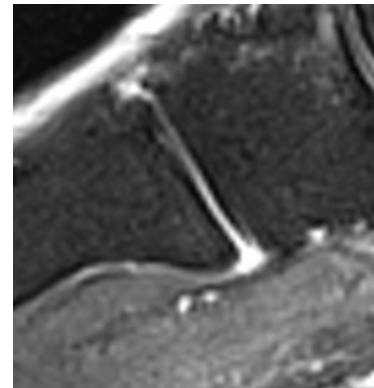
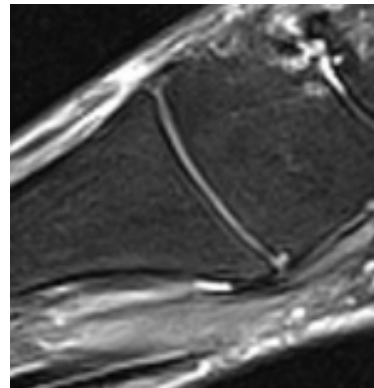
0

1

T2-weighted  
Long axis



T2-weighted  
Sagittal plane

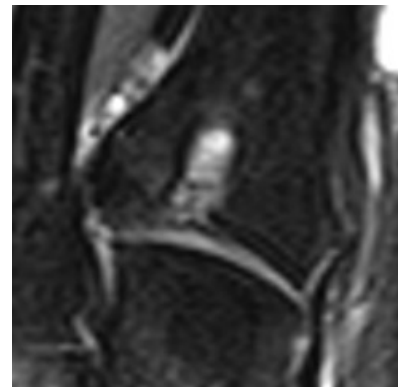
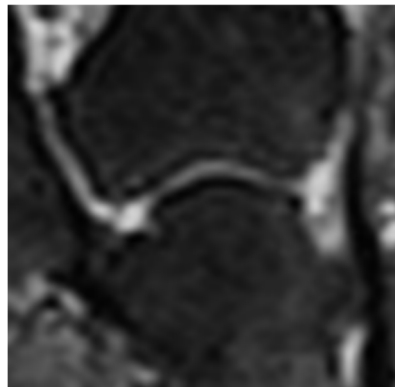


First Tarso-metatarsal Joint  
Subchondral Cyst

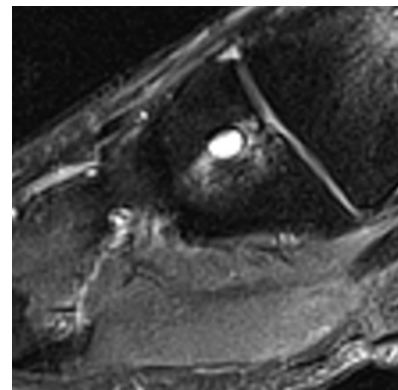
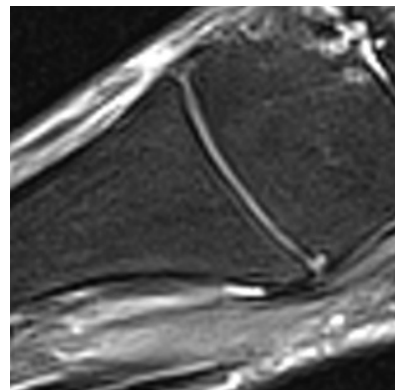
0

1

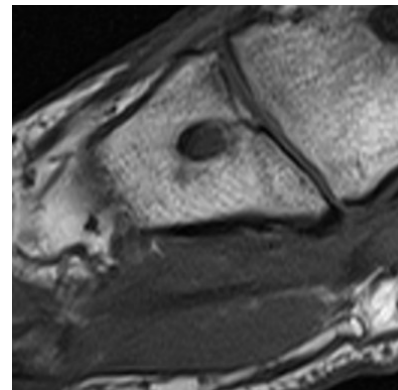
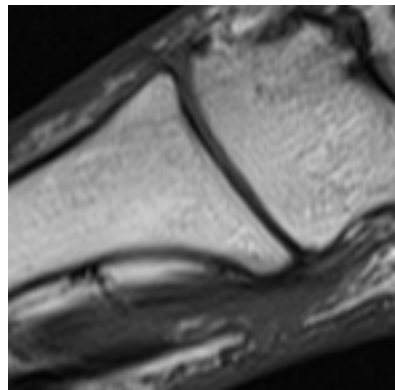
T2-weighted  
Long axis



T2-weighted  
Sagittal plane



T1-weighted  
Sagittal plane



First Tarso-metatarsal Joint  
Bone Marrow Lesion

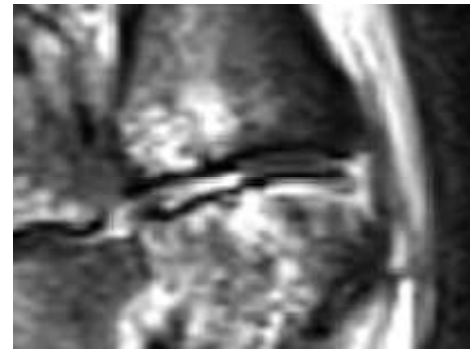
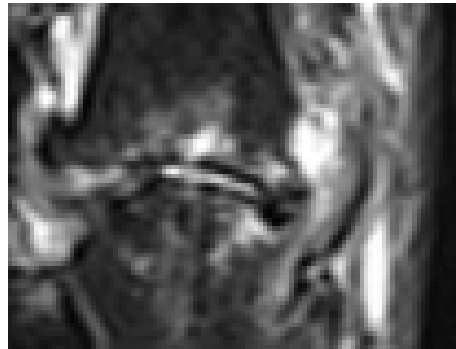
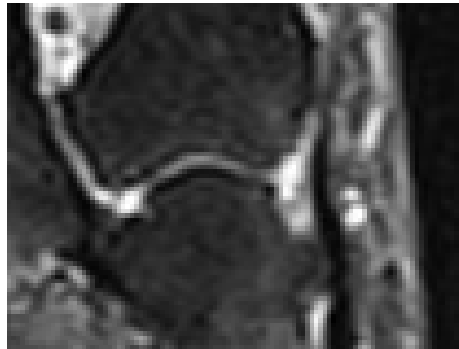0

1


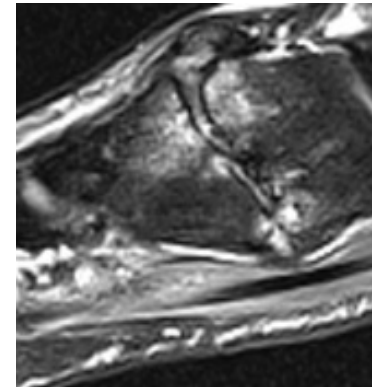
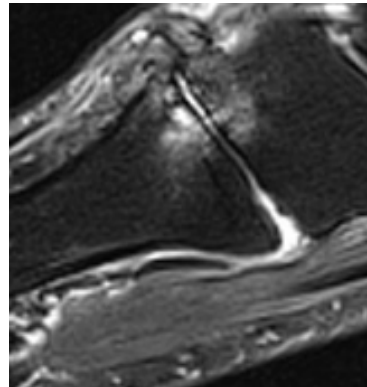
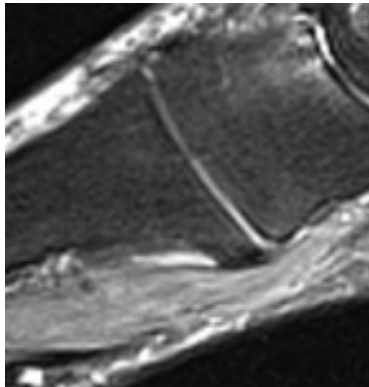
2

3

T2-weighted  
Long axis



T2-weighted  
Sagittal plane





Second Tarso-metatarsal Joint  
Joint Space Narrowing

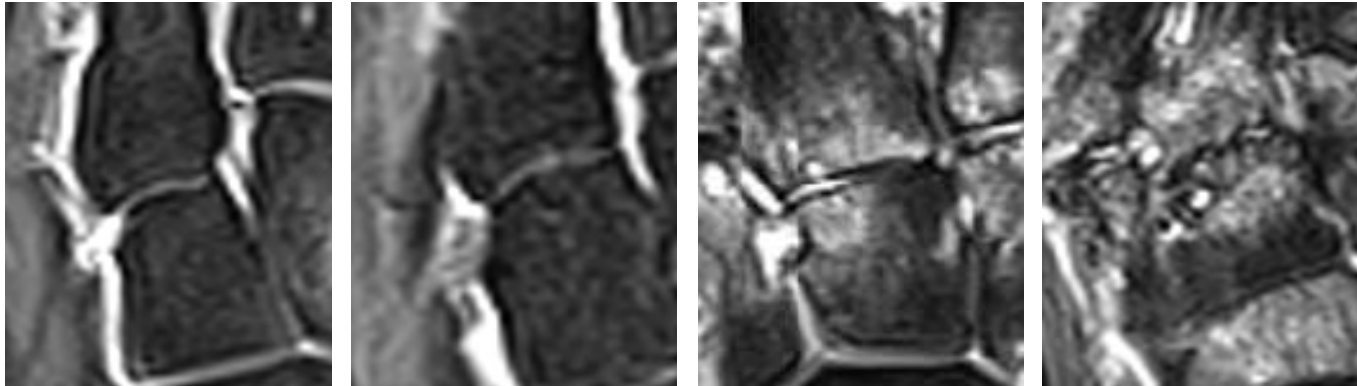
0

1

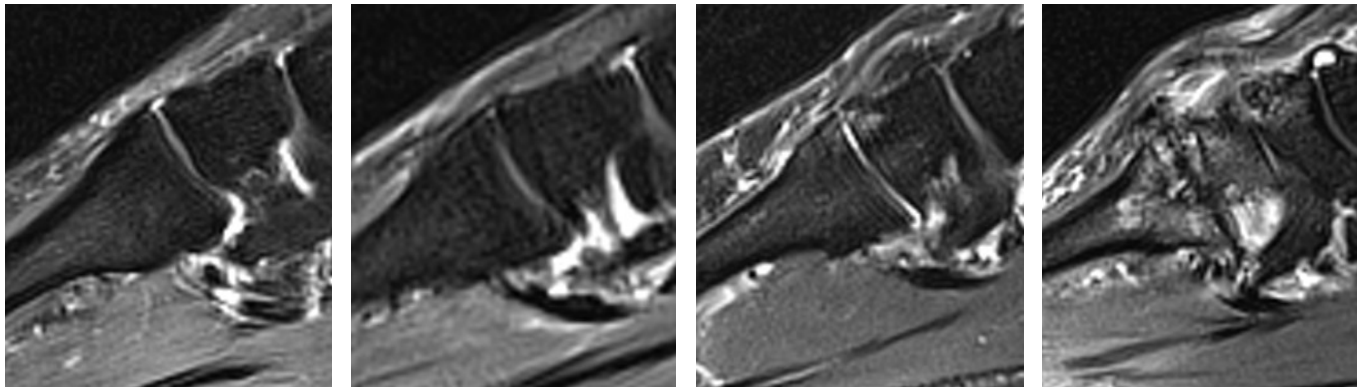
2

3

T2-weighted  
Long axis

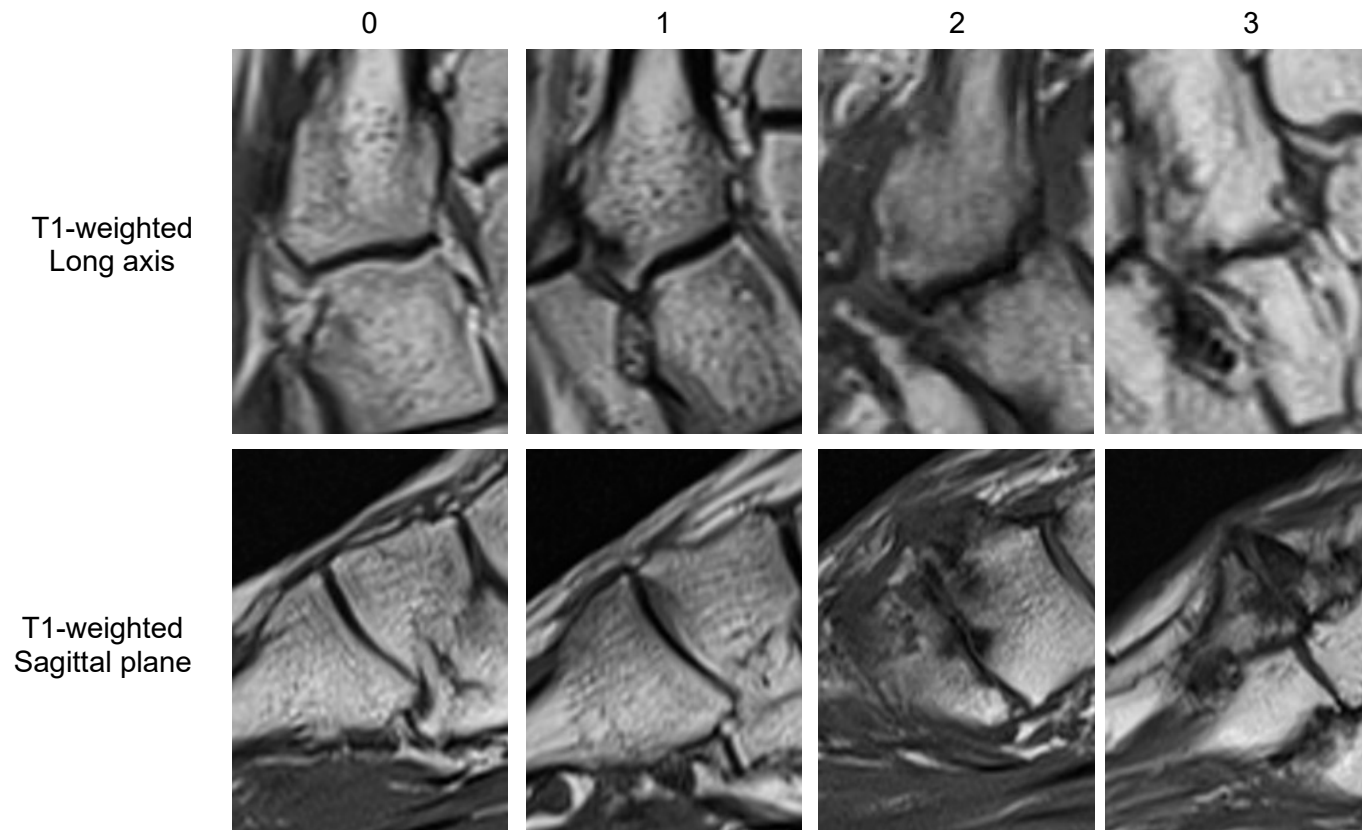


T2-weighted  
Sagittal plane





Second Tarso-metatarsal Joint  
Osteophytes

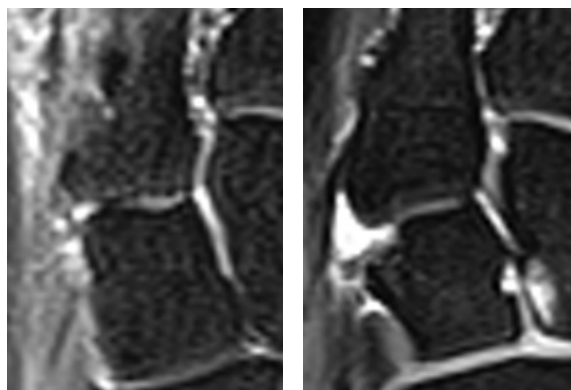


Second Tarso-metatarsal Joint  
Effusion-Synovitis

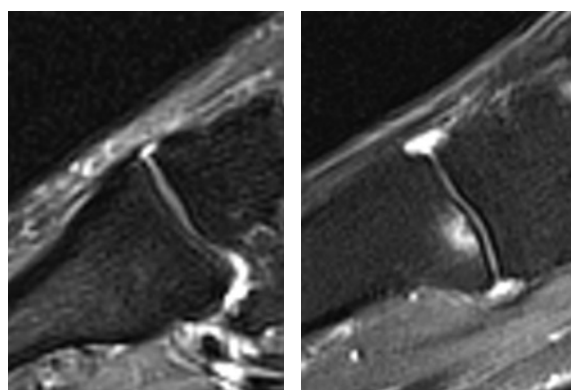
0

1

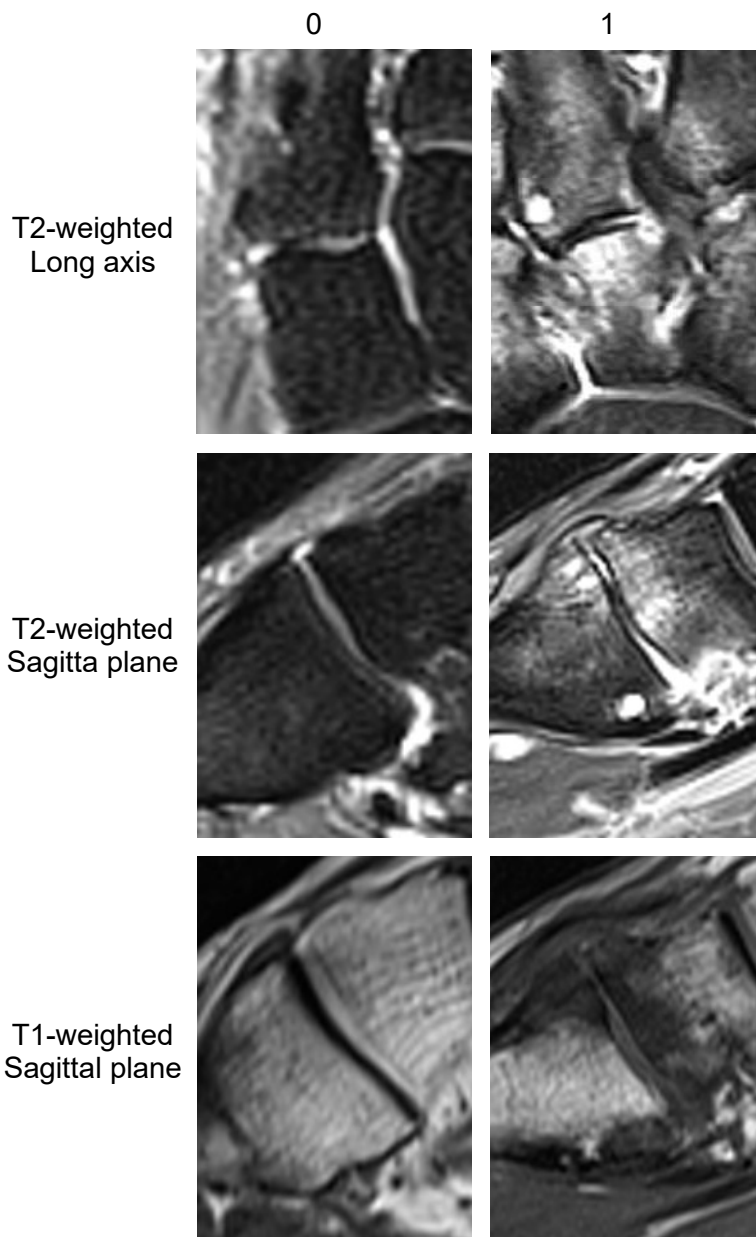
T2-weighted  
Long axis



T2-weighted  
Sagittal plane



Second Tarso-metatarsal Joint  
Subchondral Cyst



Second Tarso-metatarsal Joint  
Bone Marrow Lesion

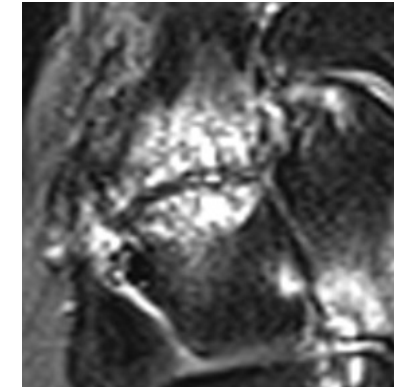
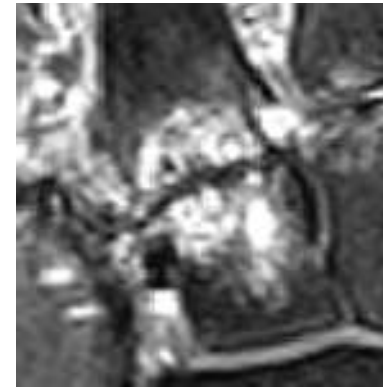
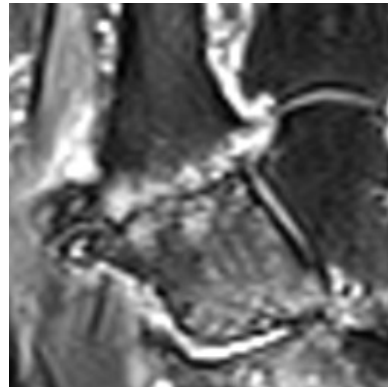
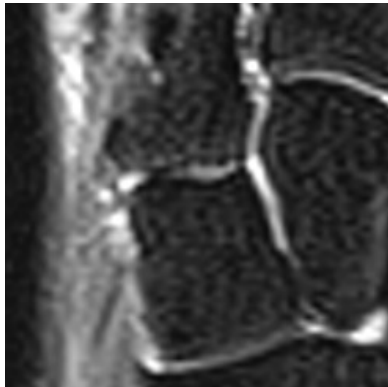
0

1

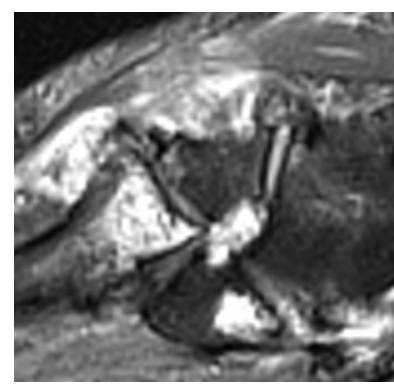
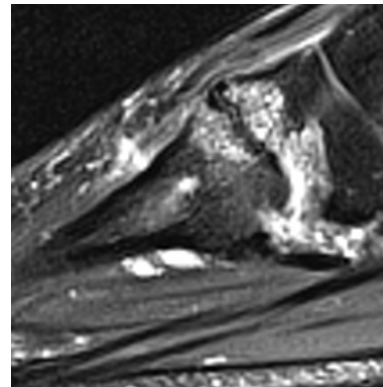
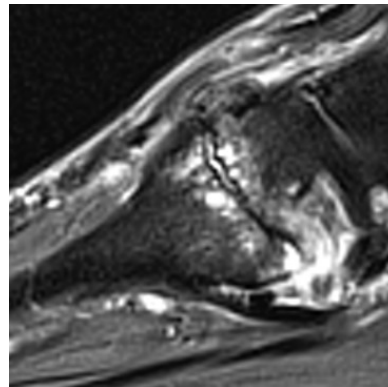
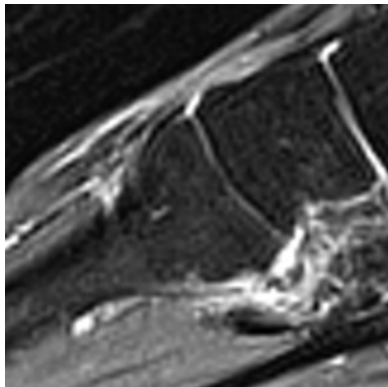
2

3

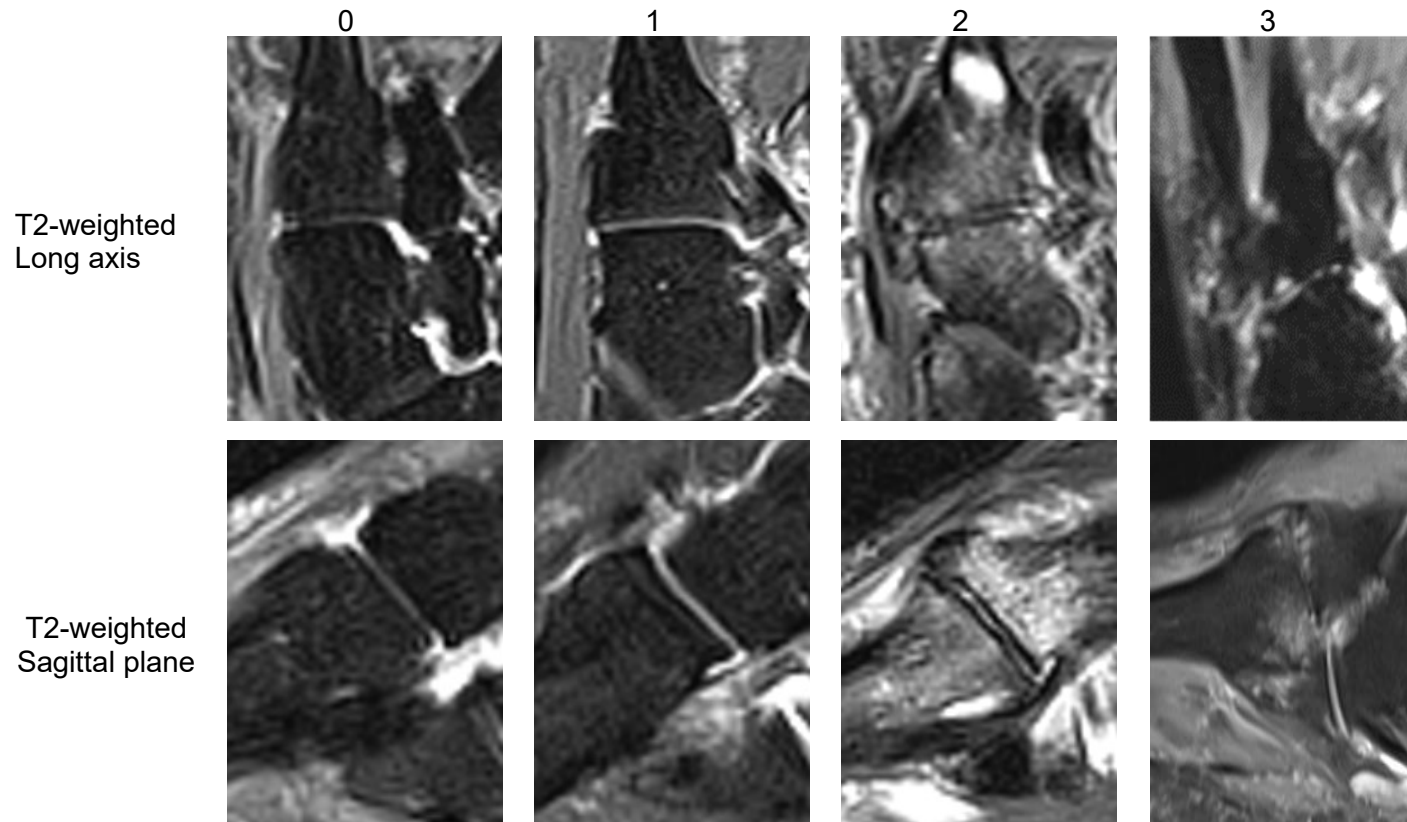
T2-weighted  
Long axis



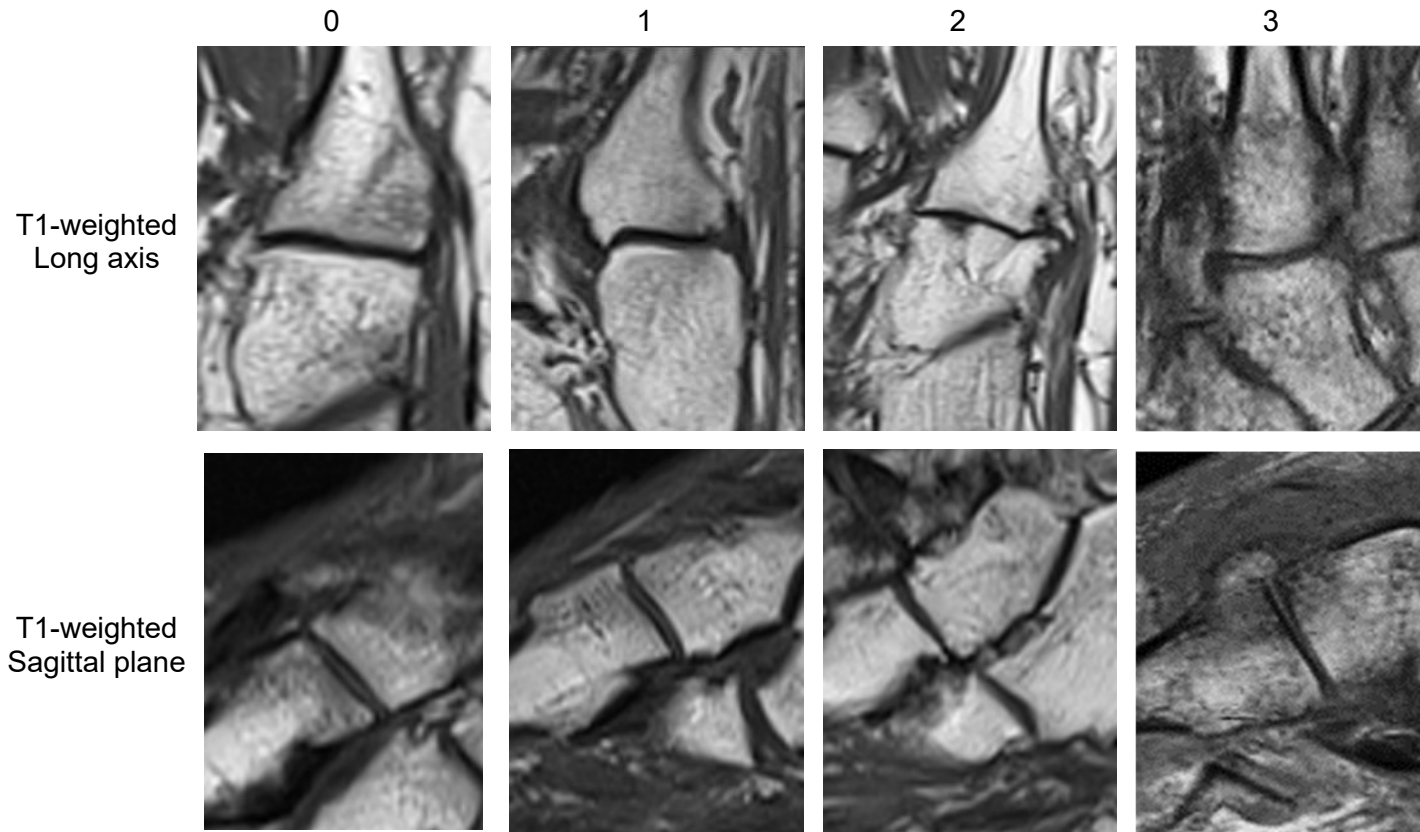
T2-weighted  
Sagittal plane



Third Tarso-metatarsal Joint  
Joint Space Narrowing



Third Tarso-metatarsal Joint  
Osteophytes

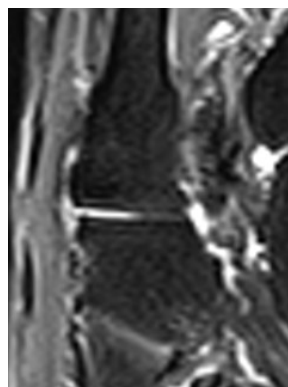
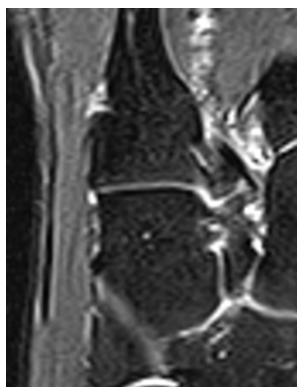


Third Tarso-metatarsal Joint  
Effusion-Synovitis

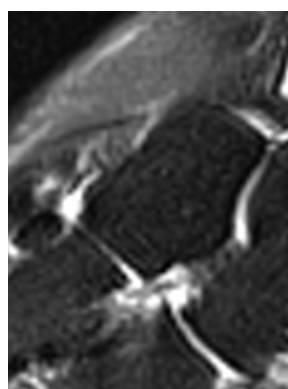
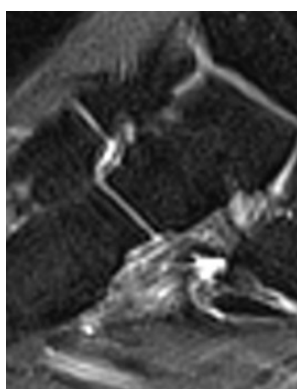
0

1

Short tau  
inversion  
recovery  
Long axis

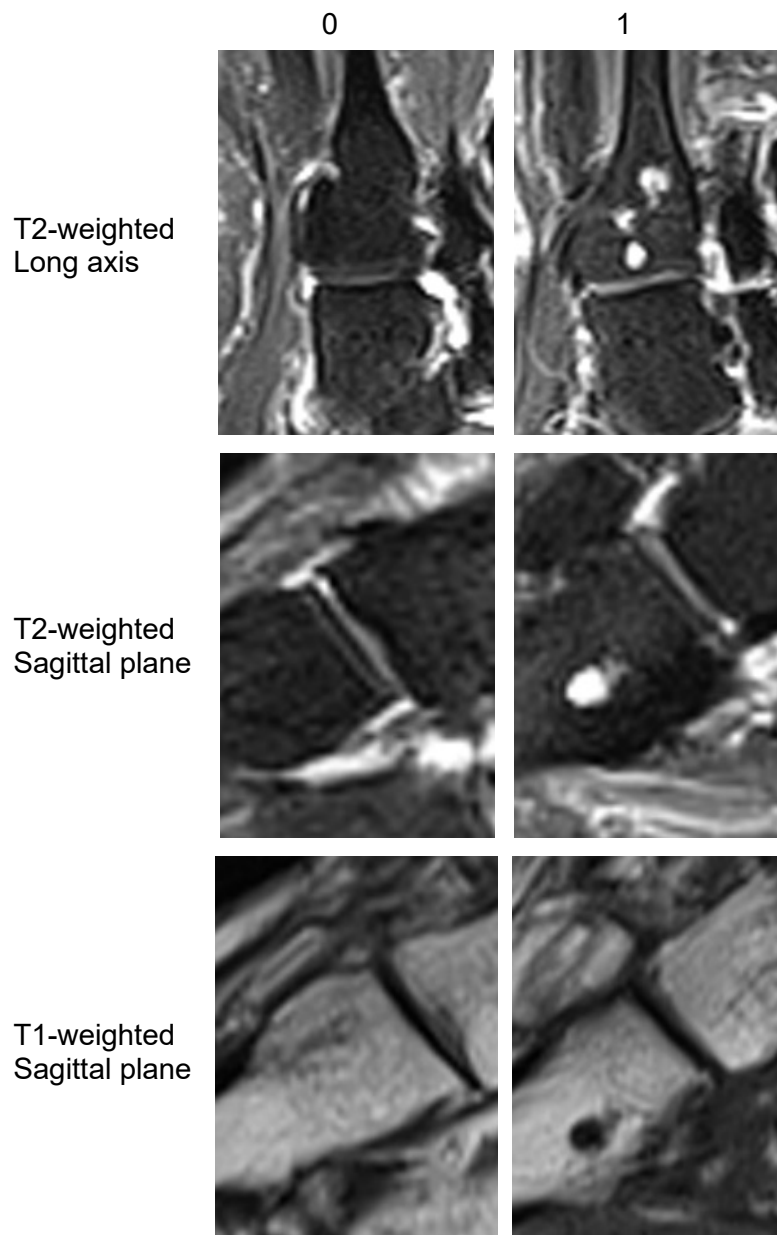


T2-weighted  
Sagittal plane





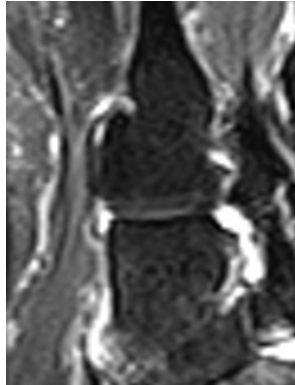
Third Tarso-metatarsal Joint  
Subchondral Cyst



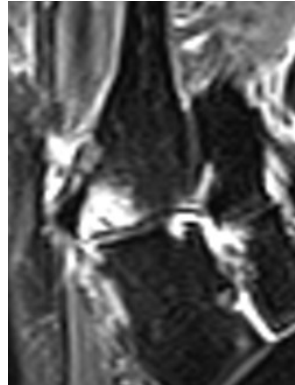

Third Tarso-metatarsal Joint  
Bone Marrow Lesion

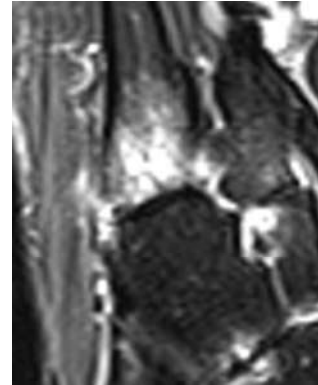
0



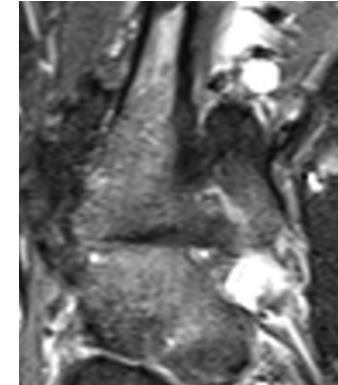
1



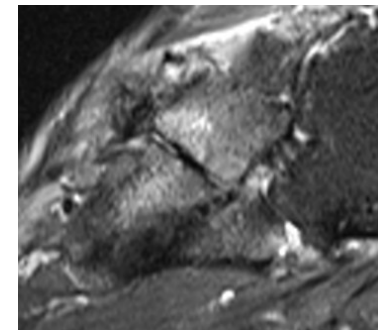
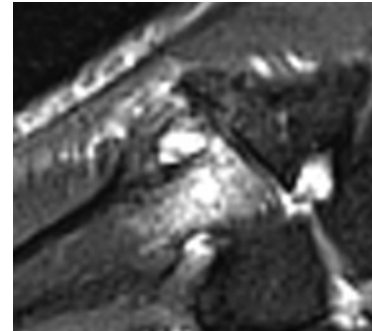
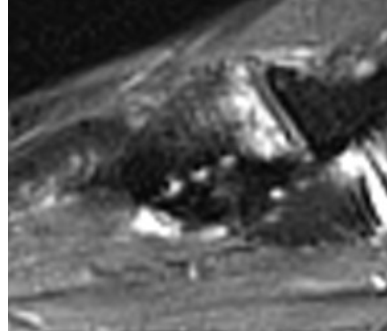
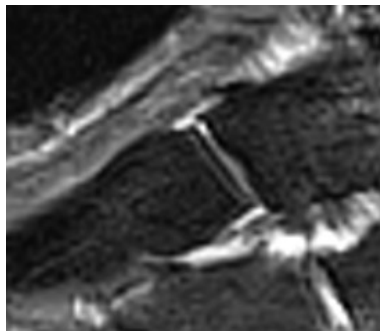
2



3

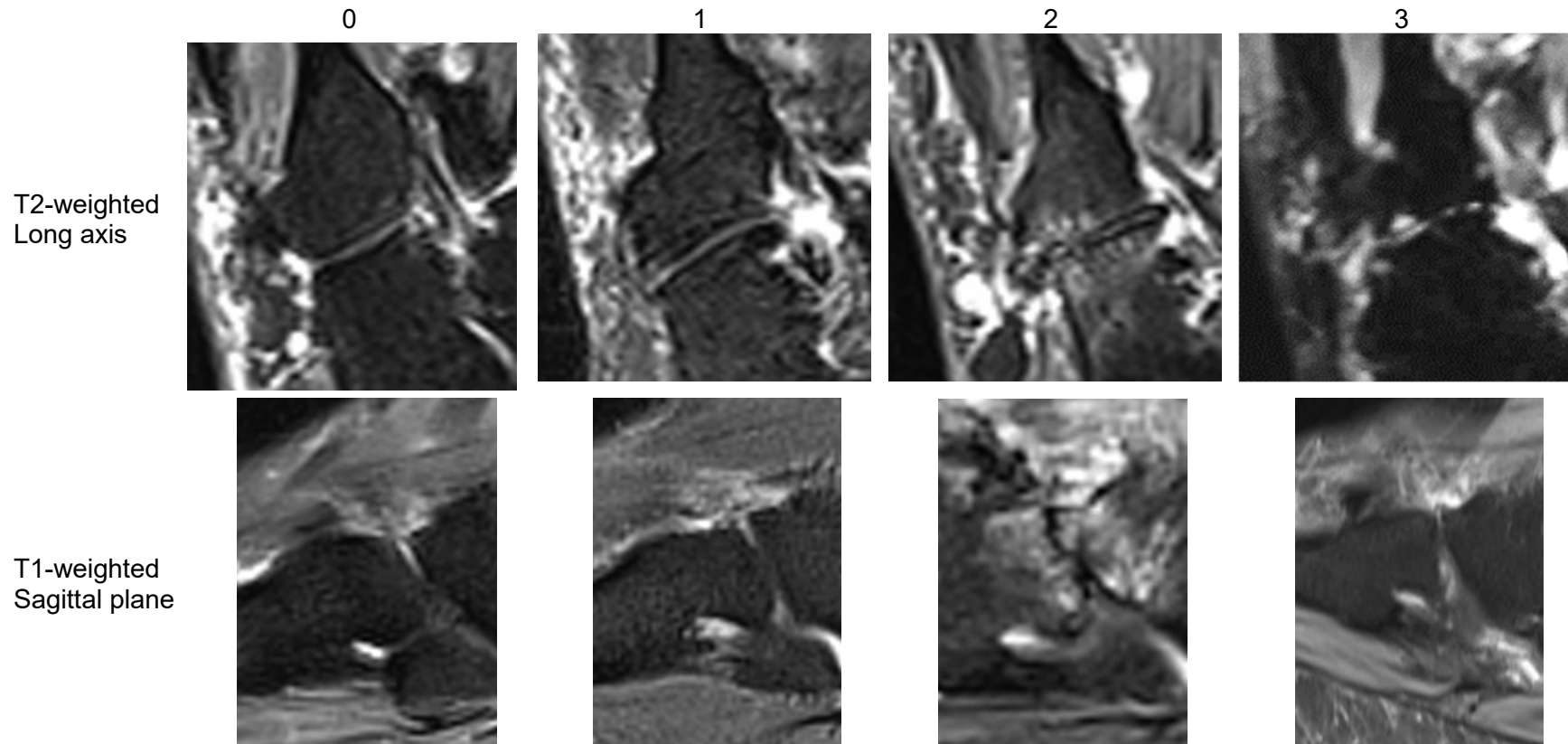


T2-weighted  
& Short tau  
inversion  
recovery  
Long axis

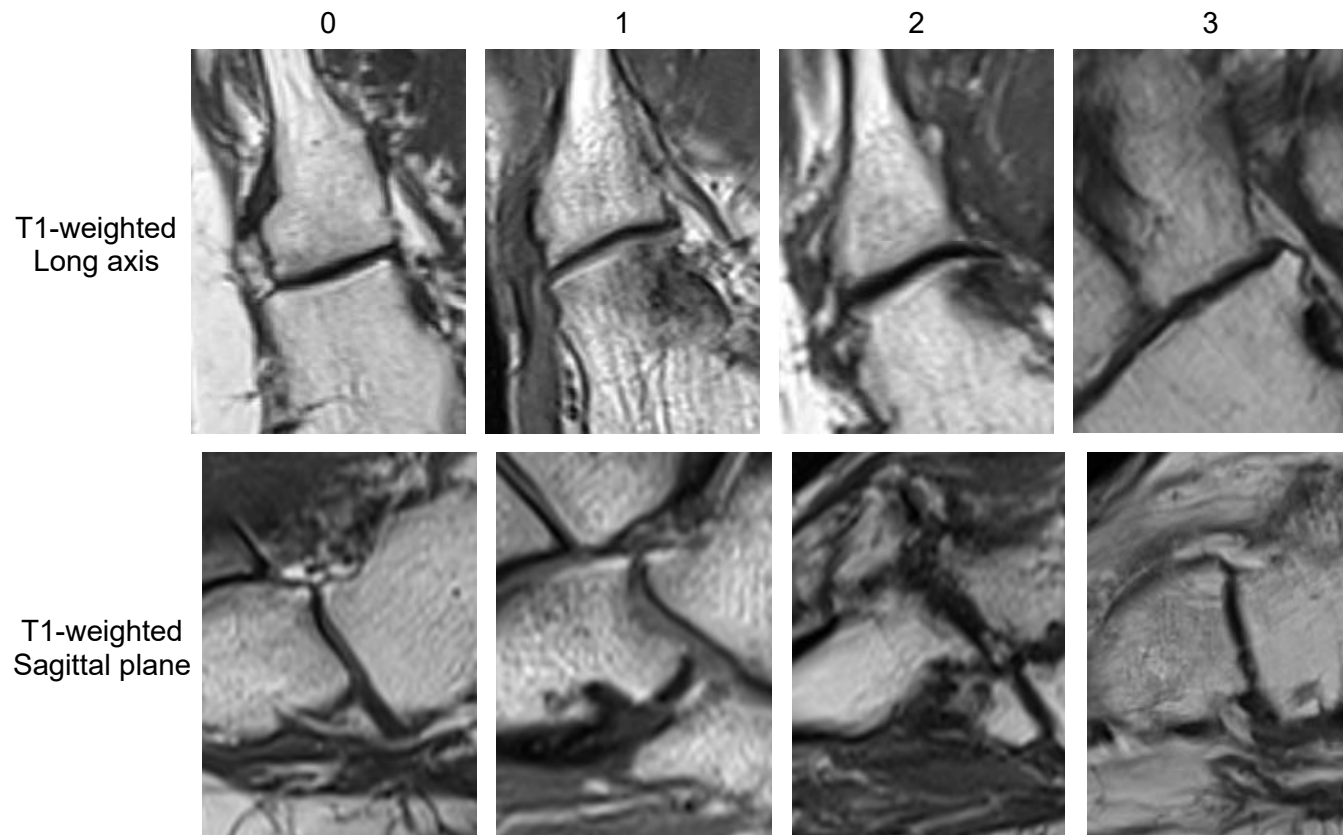


T2-weighted  
Sagittal plane

Fourth Tarso-metatarsal Joint  
Joint Space Narrowing



Fourth Tarso-metatarsal Joint  
Osteophytes

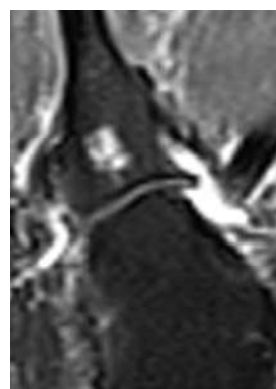
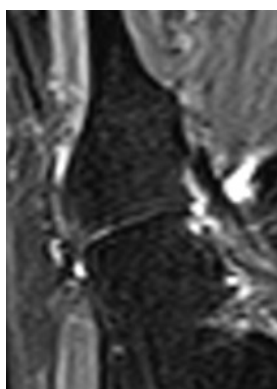


Fourth Tarso-metatarsal Joint  
Effusion-Synovitis

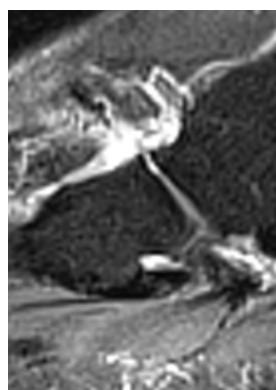
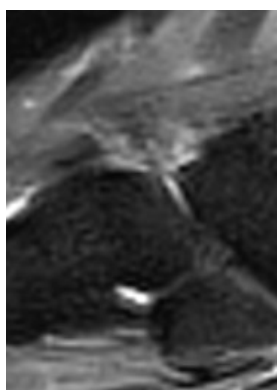
0

1

T2-weighted  
Long axis



T2-weighted  
Sagittal plane

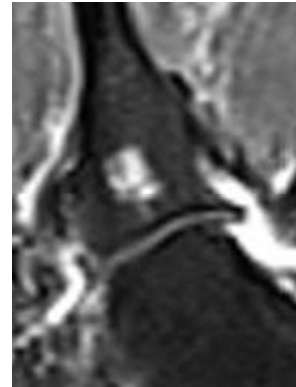
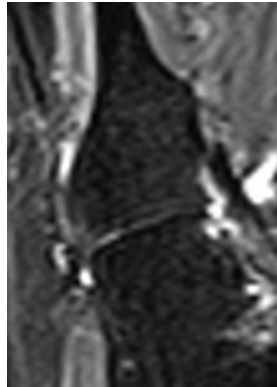


Fourth Tarso-metatarsal Joint  
Subchondral Cyst


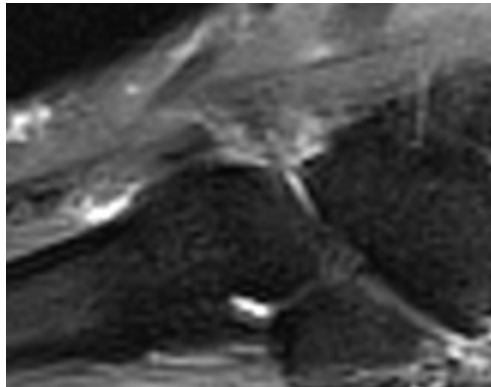
0

1

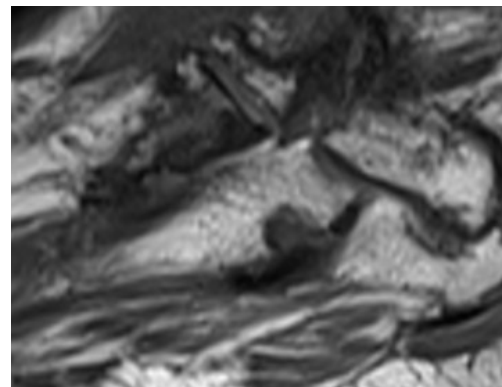
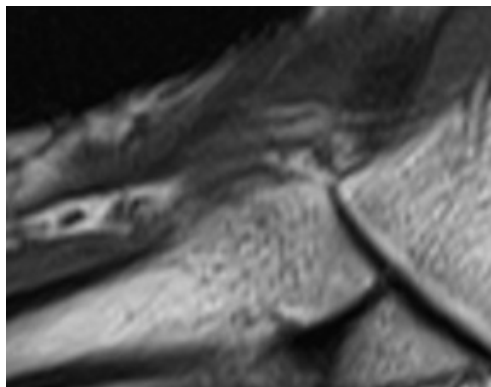
T2-weighted  
Long axis



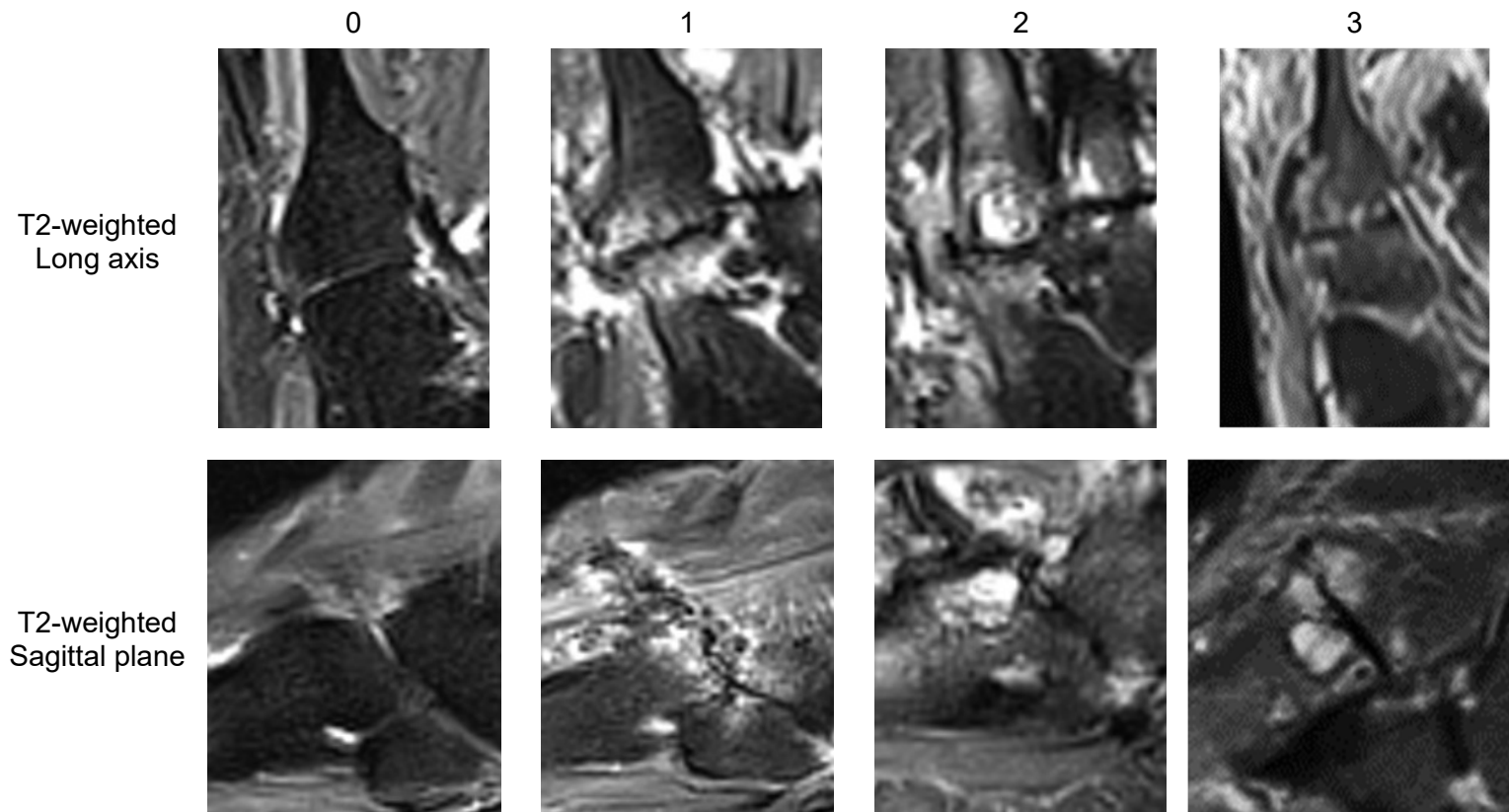
T2-weighted  
Sagittal plane



T1-weighted  
Sagittal plane



Fourth Tarso-metatarsal Joint  
Bone Marrow Lesion





Fifth Tarso-metatarsal Joint  
Joint Space Narrowing

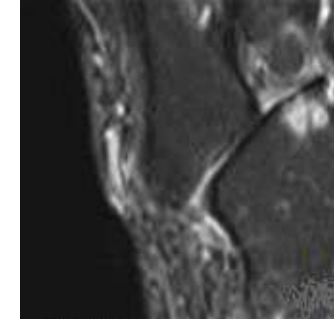
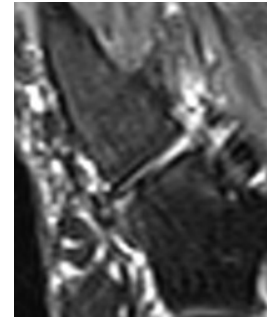
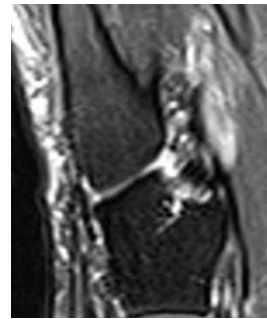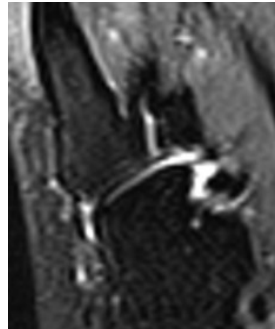
0

1

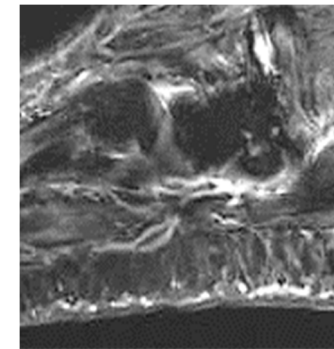
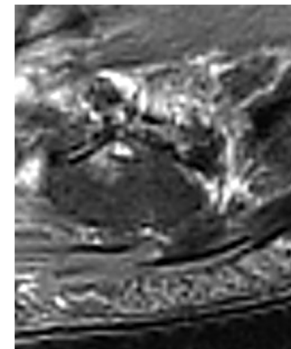

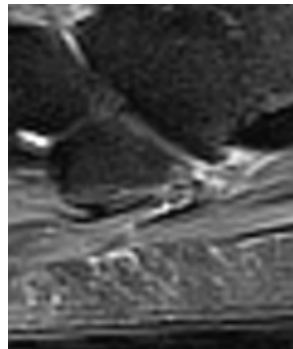
2

3

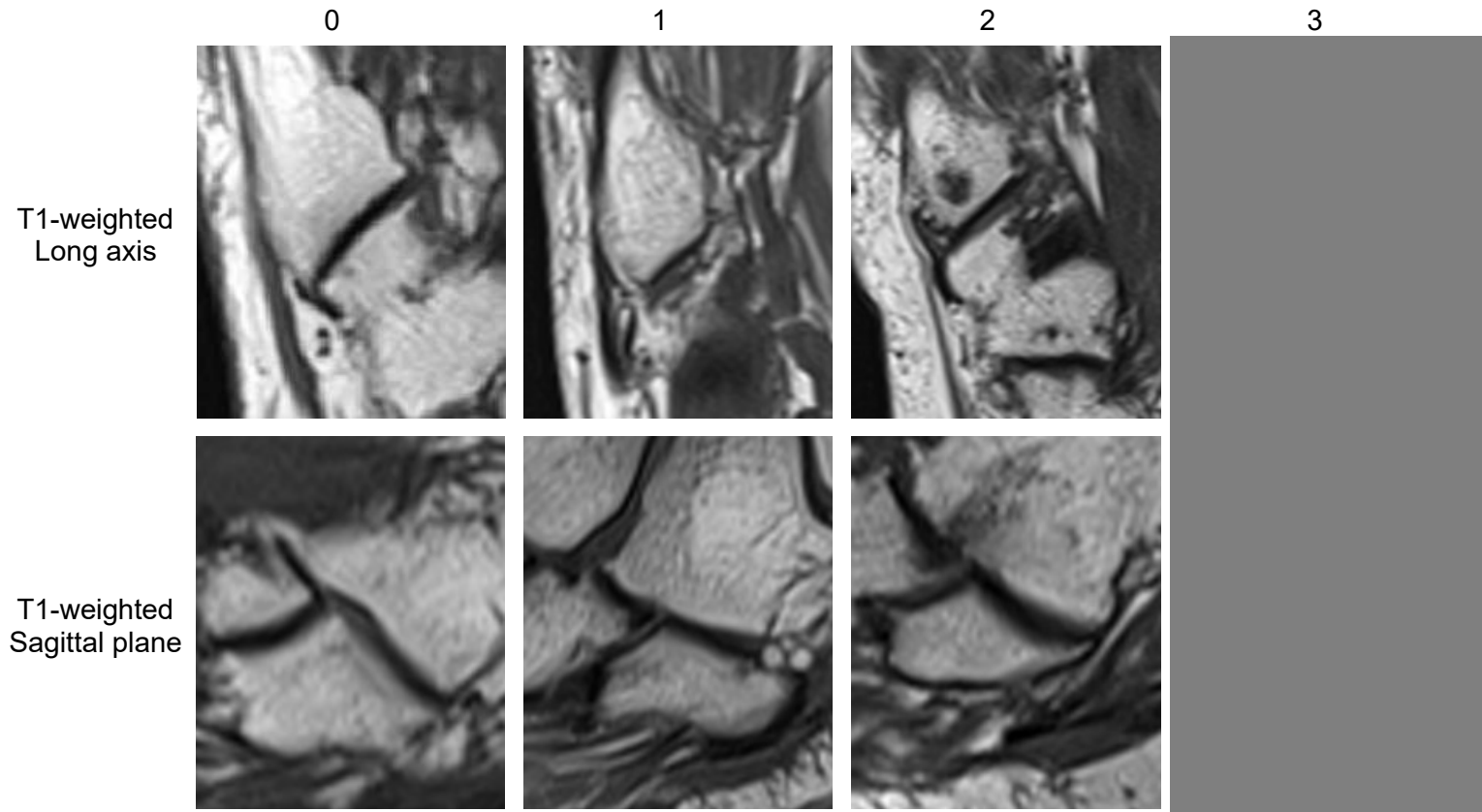
T2-weighted  
Long axis



T2-weighted  
Sagittal plane



Fifth Tarso-metatarsal Joint  
Osteophytes



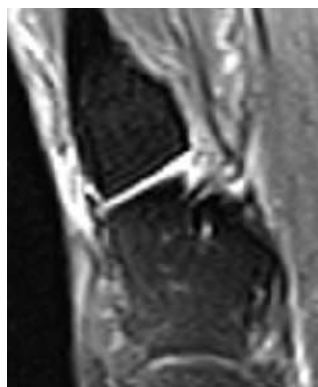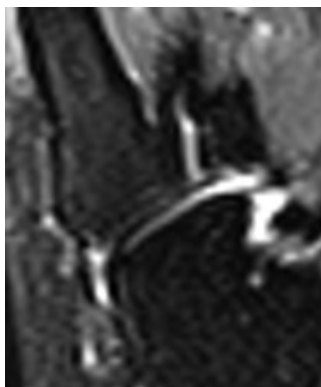


Fifth Tarso-metatarsal Joint  
Effusion-Synovitis

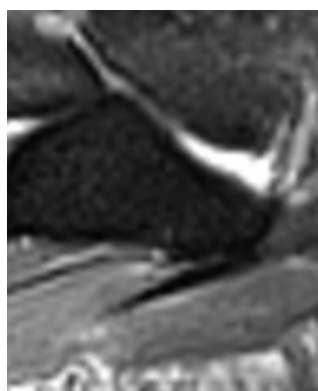
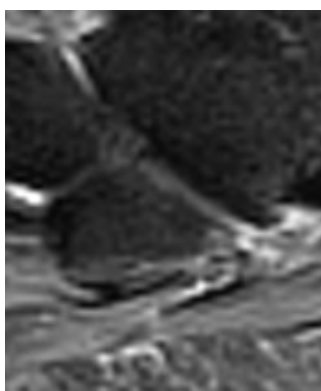
0

1

Short tau  
inversion  
recovery  
Long axis



T2-weighted  
Sagittal plane

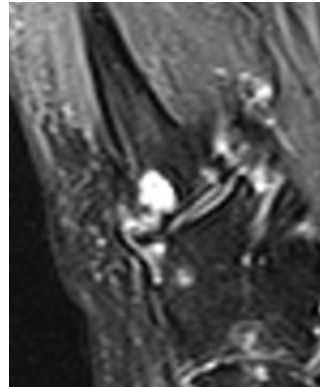
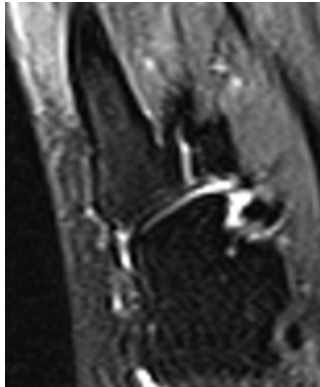


Fifth Tarso-metatarsal Joint  
Subchondral Cyst

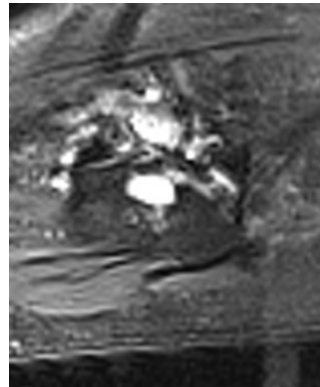
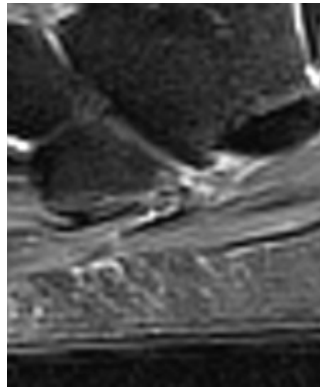
0

1

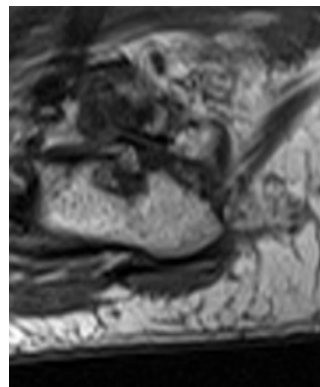
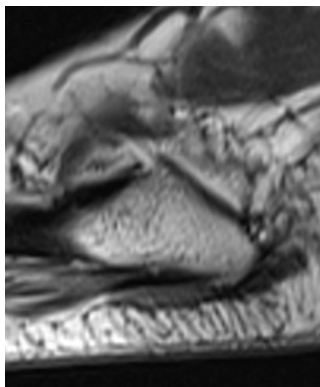
Short tau  
inversion  
recovery  
Long Axis



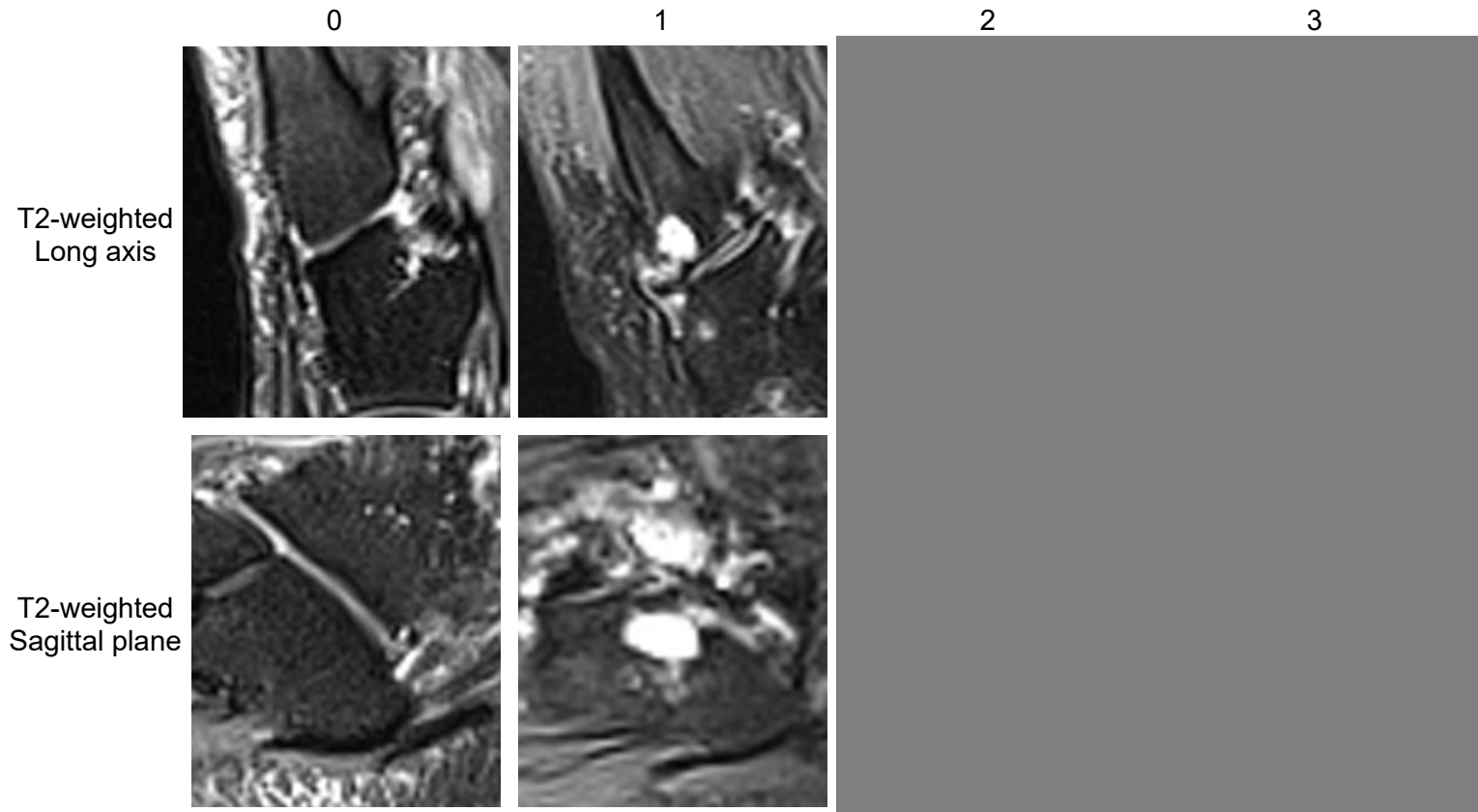
T2-weighted  
Sagittal plane



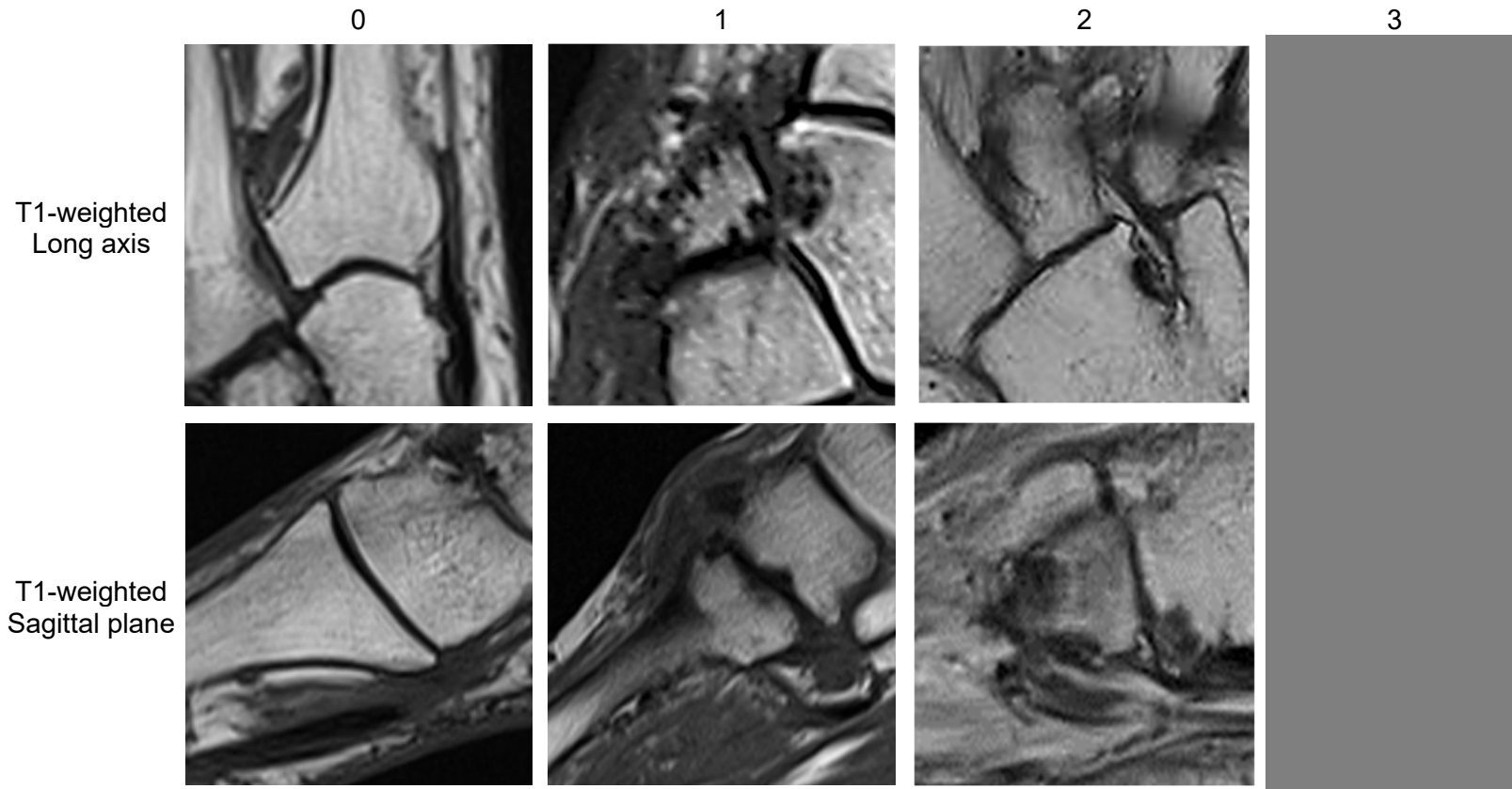
T1-weighted  
Sagittal plane



Fifth Tarso-metatarsal Joint  
Bone Marrow Lesion



Tarso-metatarsal Score  
Bone Erosion exemplar



Tarsal Bone Scores  
Talus Bone Marrow Lesion

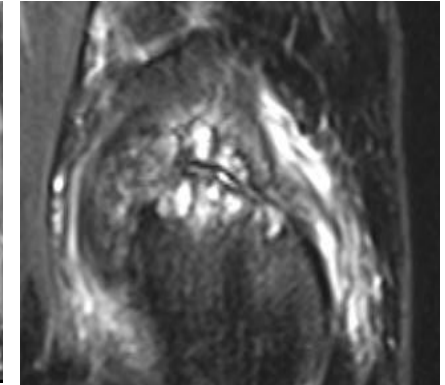
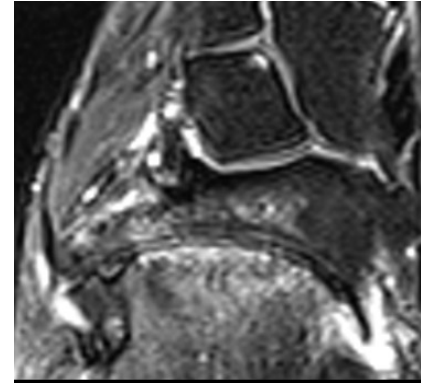
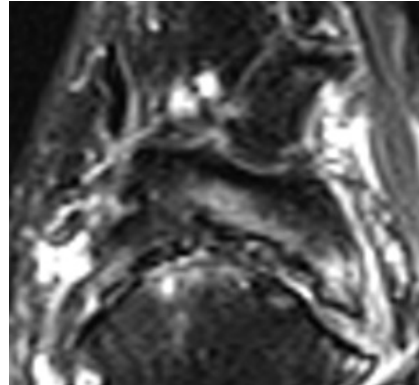
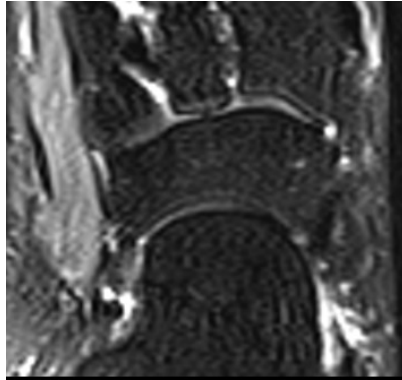
0

1

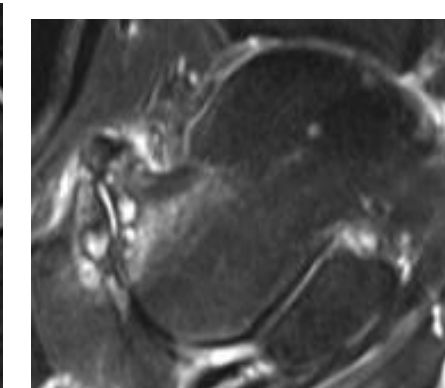
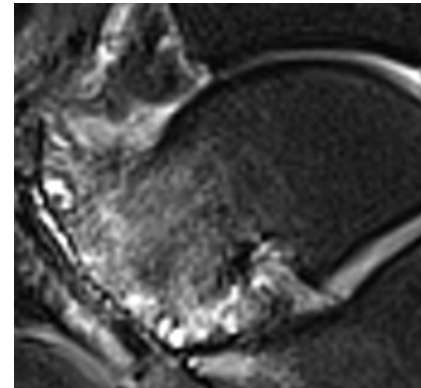
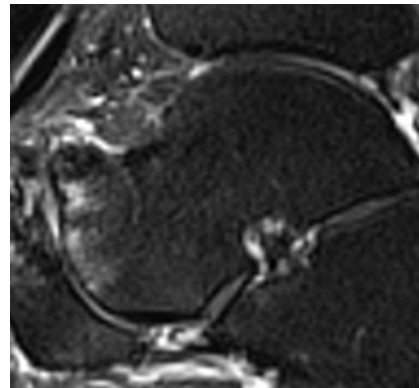
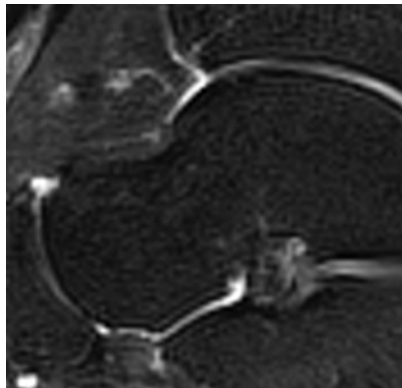
2

3

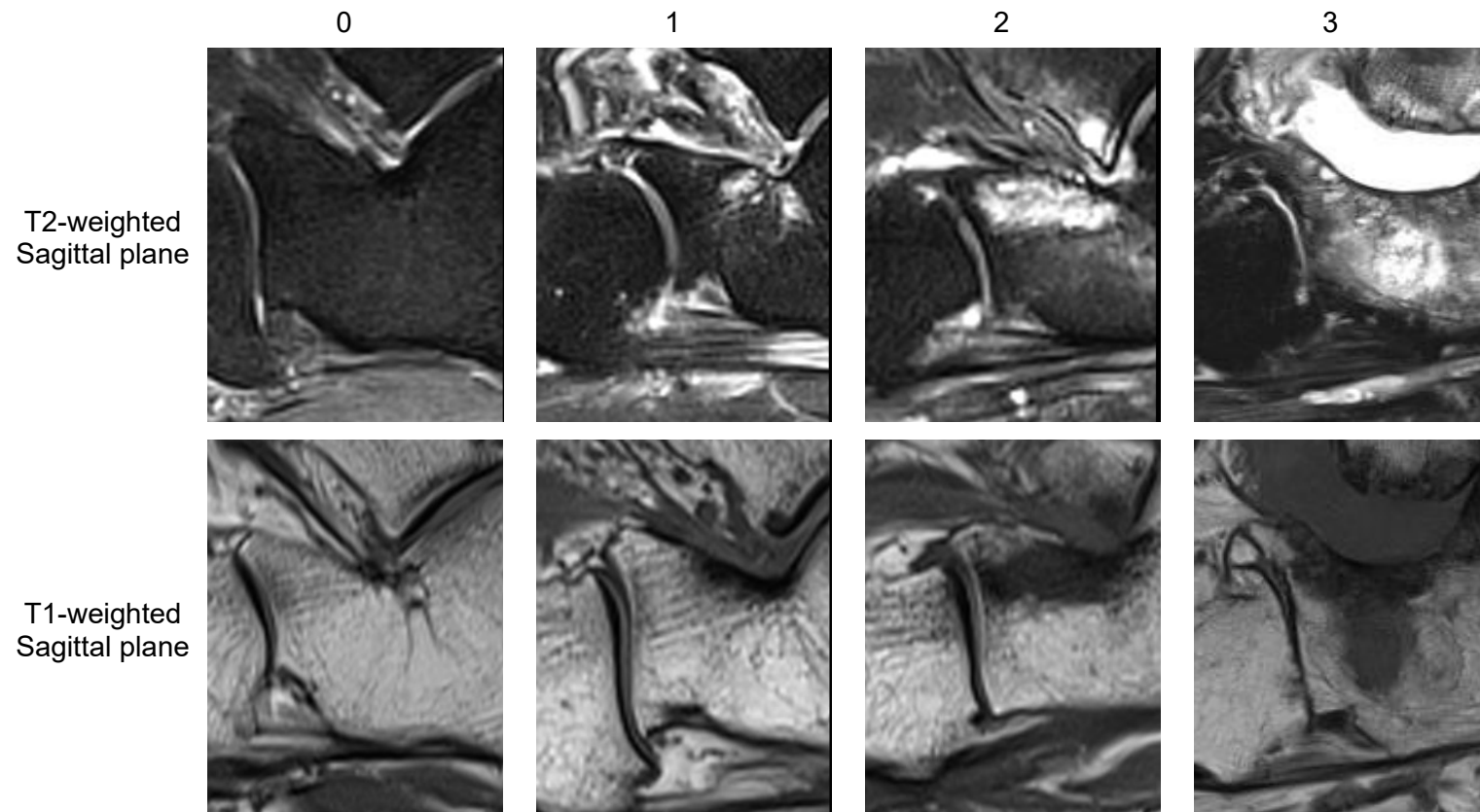
T1-weighted  
Long axis



T1-weighted  
Sagittal plane



Tarsal Bone Scores  
Calcaneus Bone Marrow Lesion





Tarsal Bone Scores  
Navicular Bone Marrow Lesion

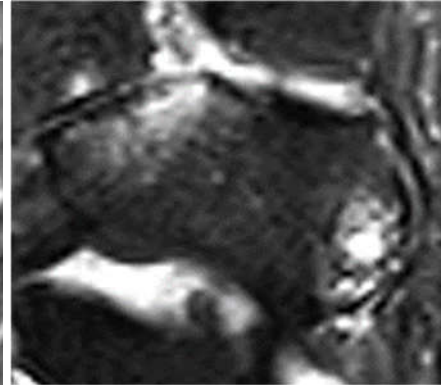
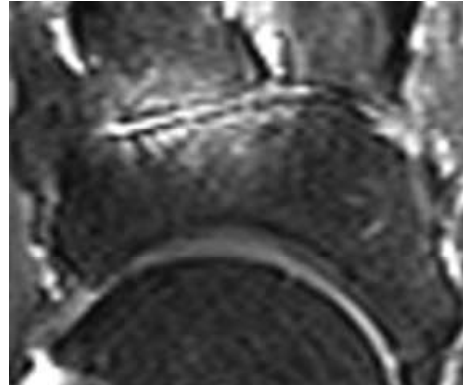
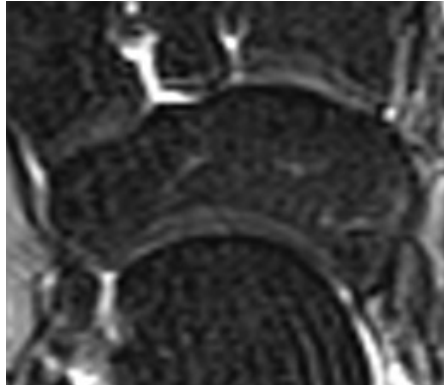
0

1

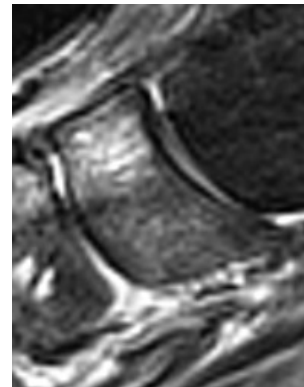
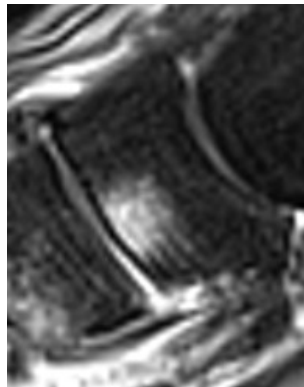
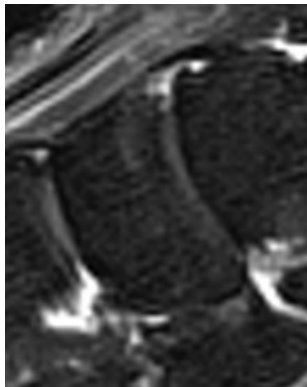
2

3

T2-weighted  
Long axis



T2-weighted  
Sagittal plane



Tarsal Bone Scores  
Medial Cuneiform Bone Marrow Lesion

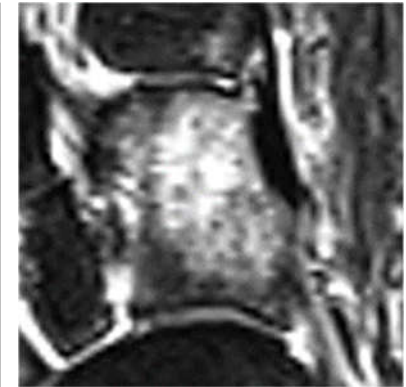
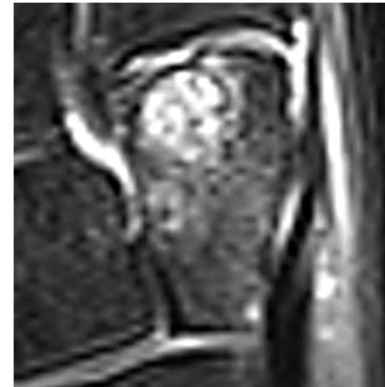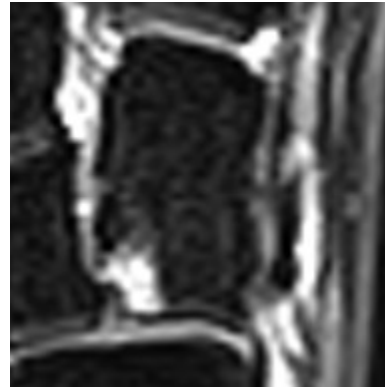
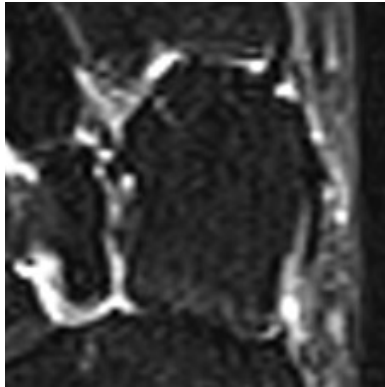
0

1

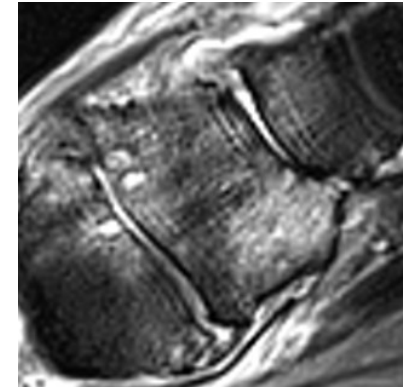
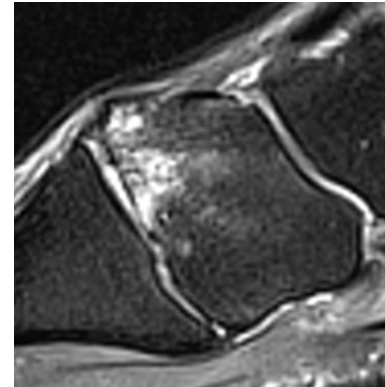
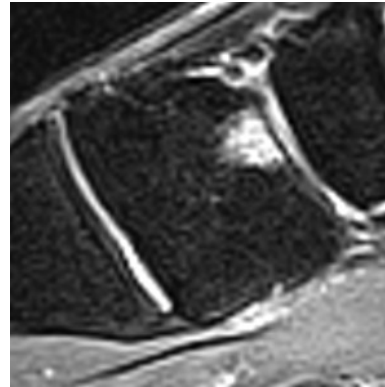
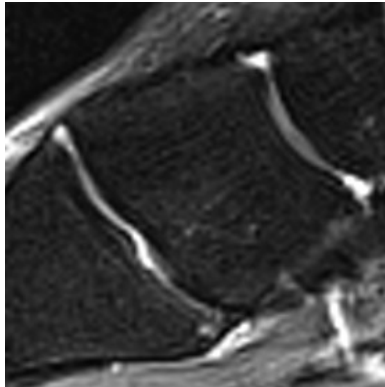
2

3

T2-weighted  
Long axis



T2-weighted  
Sagittal plane





Tarsal Bone Scores  
Intermediate Cuneiform Bone Marrow Lesion


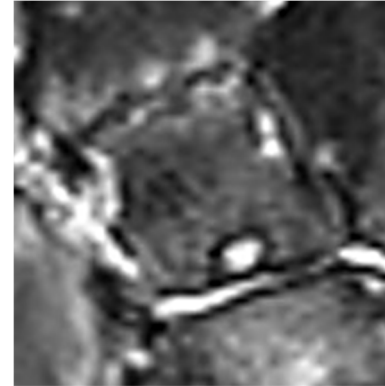
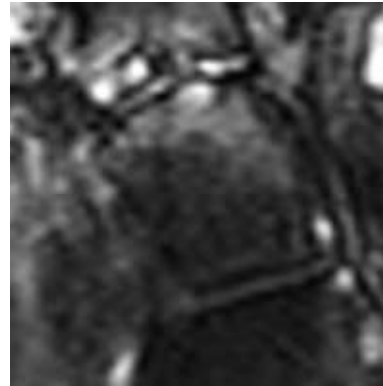
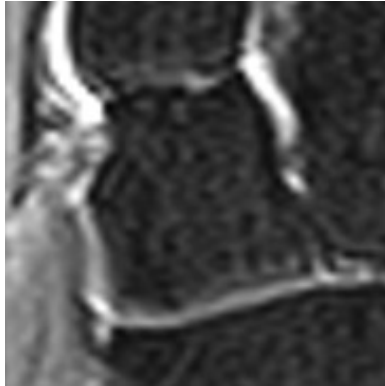
0

1

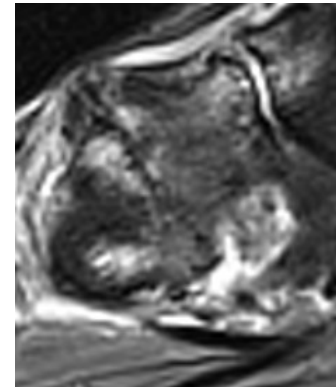
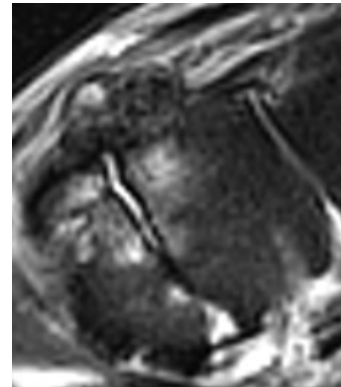
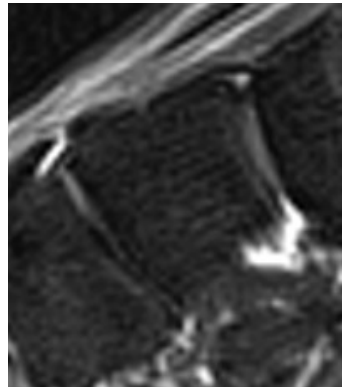
2

3

T2-weighted  
Long axis



T2-weighted  
Sagittal plane



Tarsal Bone Scores  
Lateral Cuneiform Bone Marrow Lesion

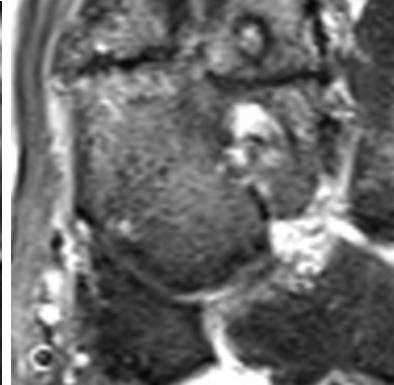
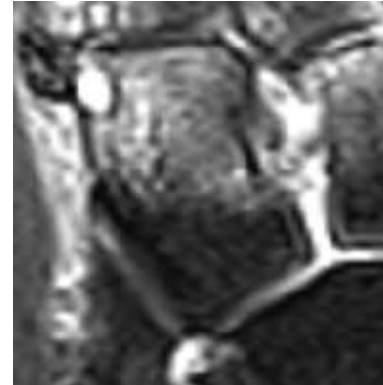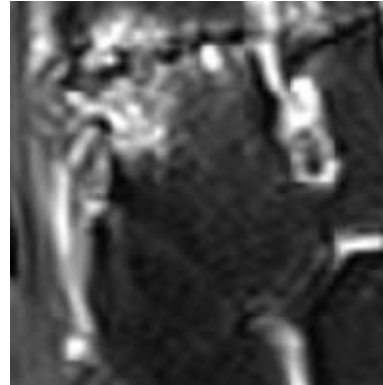
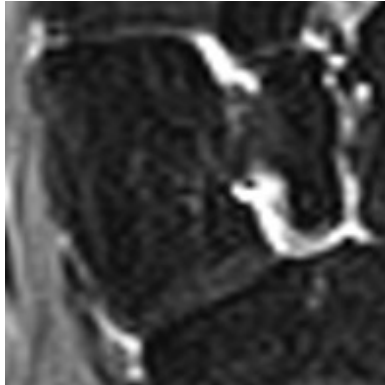
0

1

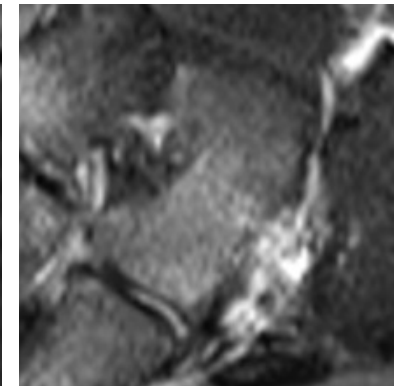
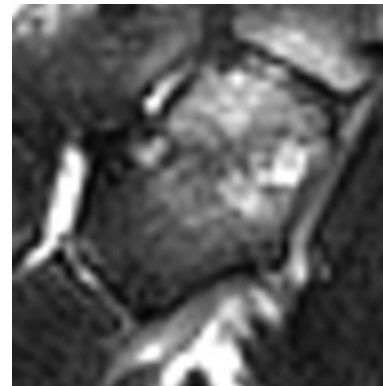
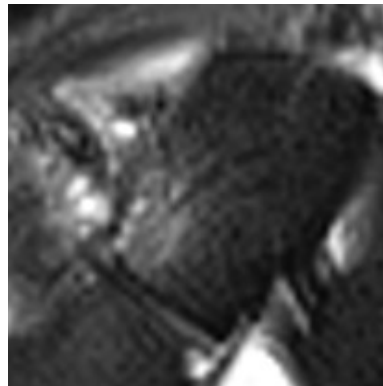
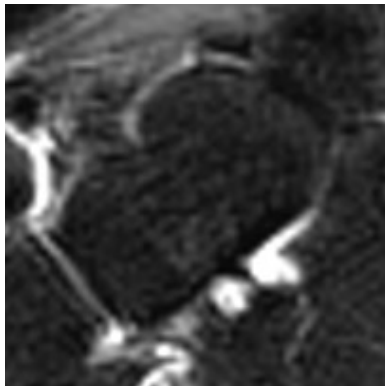
2

3

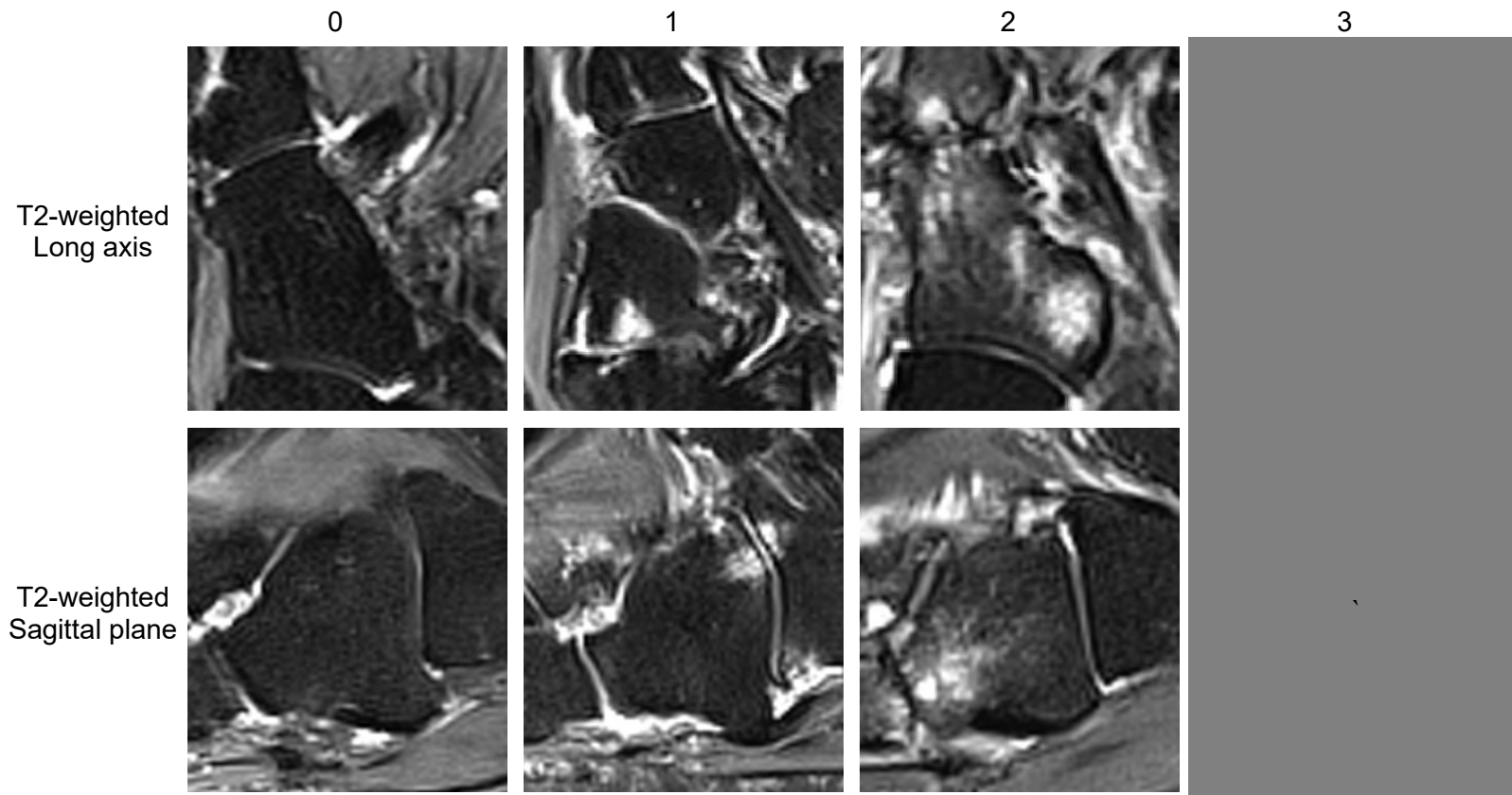
T2-weighted  
Long axis




T2-weighted  
& Short tau  
inversion  
recovery  
Sagittal plane



Tarsal Bone Scores  
Cuboid Bone Marrow Lesion



Representative Tarsal Bone Score  
Bone Erosion



Tarsal Joints  
Talo-calcaneal Joint Space Narrowing

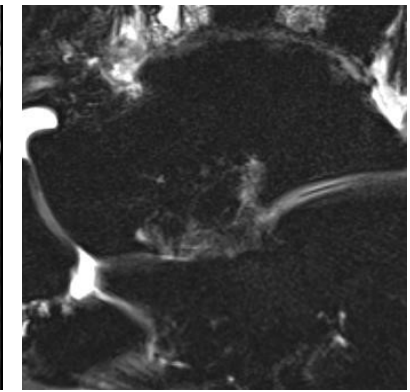
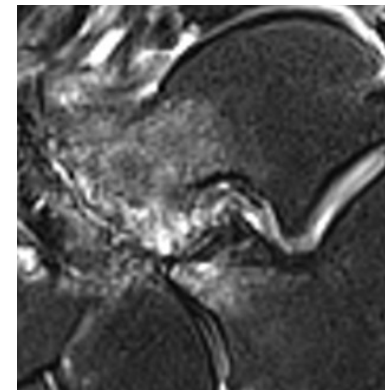
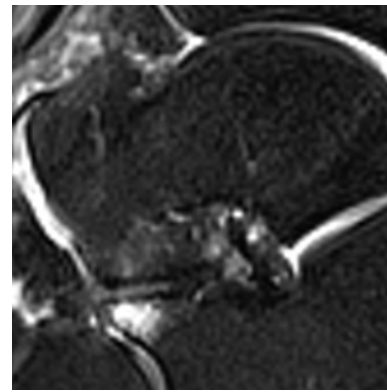
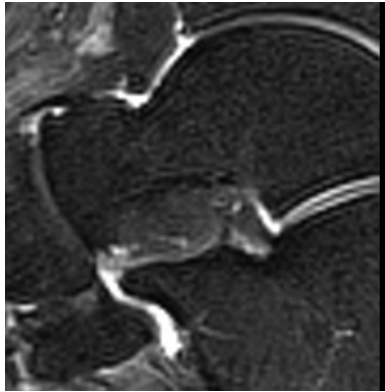
0

1

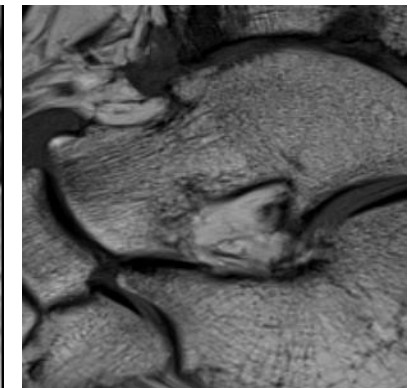
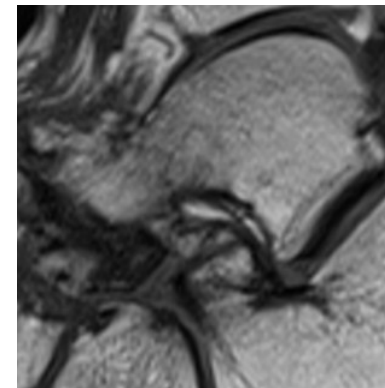
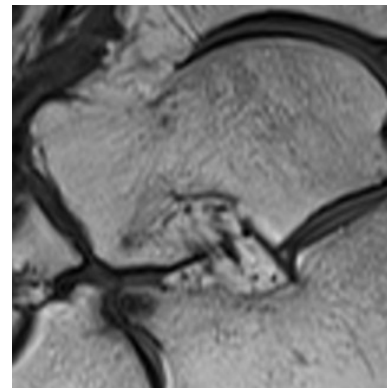
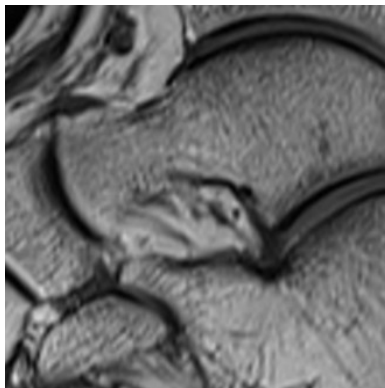
2

3

T2-weighted  
Sagittal plane



T1-weighted  
Sagittal plane





Tarsal Joints  
Talo-calcaneal Osteophytes

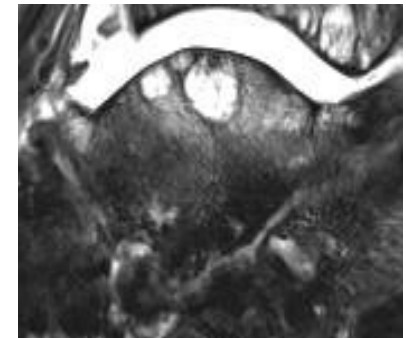
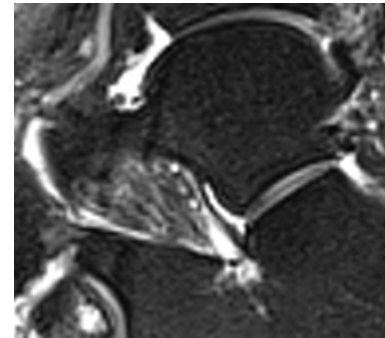
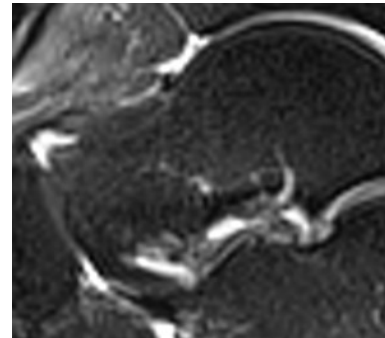
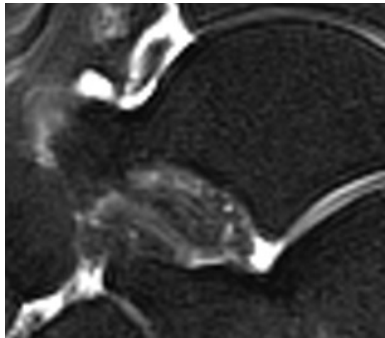
0

1

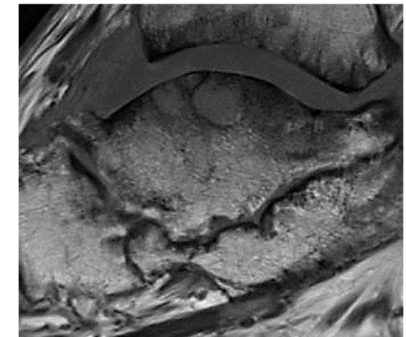
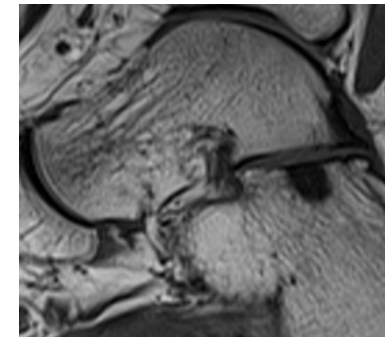
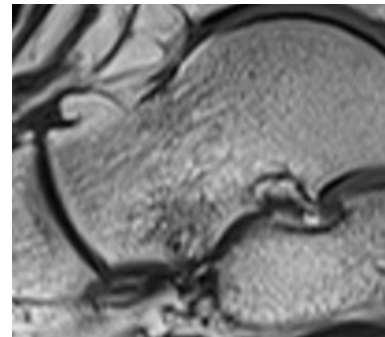
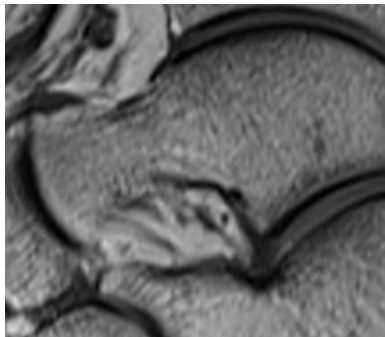
2

3

T2-weighted  
Sagittal plane



T1-weighted  
Sagittal plane

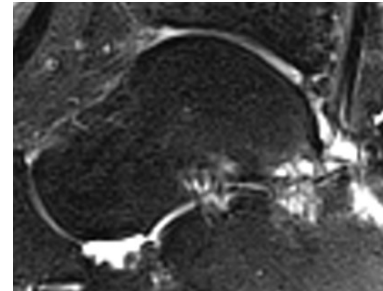
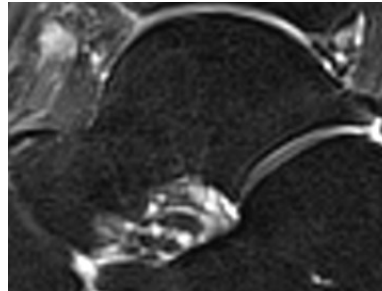


Tarsal Joints  
Talo-calcaneal Effusion-Synovitis

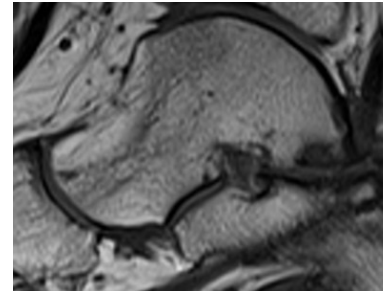
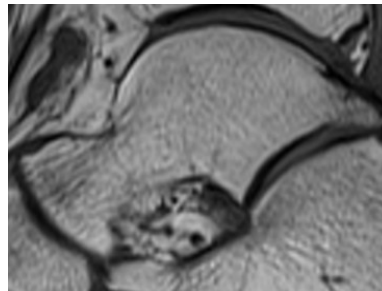
0

1

T2-weighted  
Sagittal plane



T1-weighted  
Sagittal plane

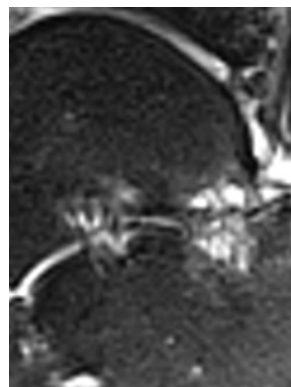
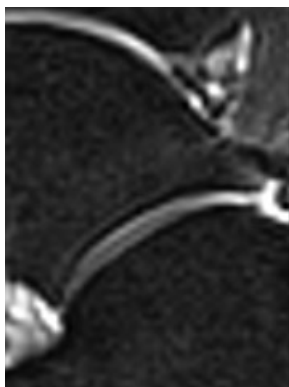

Tarsal Joints  
Talo-calcaneal Subchondral Cyst

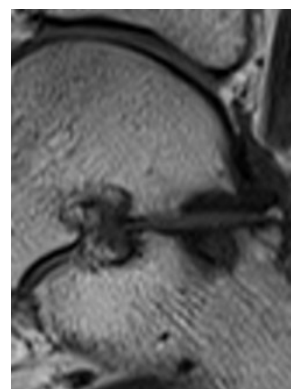
0

1

T2-weighted  
Sagittal plane



T1-weighted  
Sagittal plane





Tarsal Joints  
Talo-navicular Joint Space Narrowing

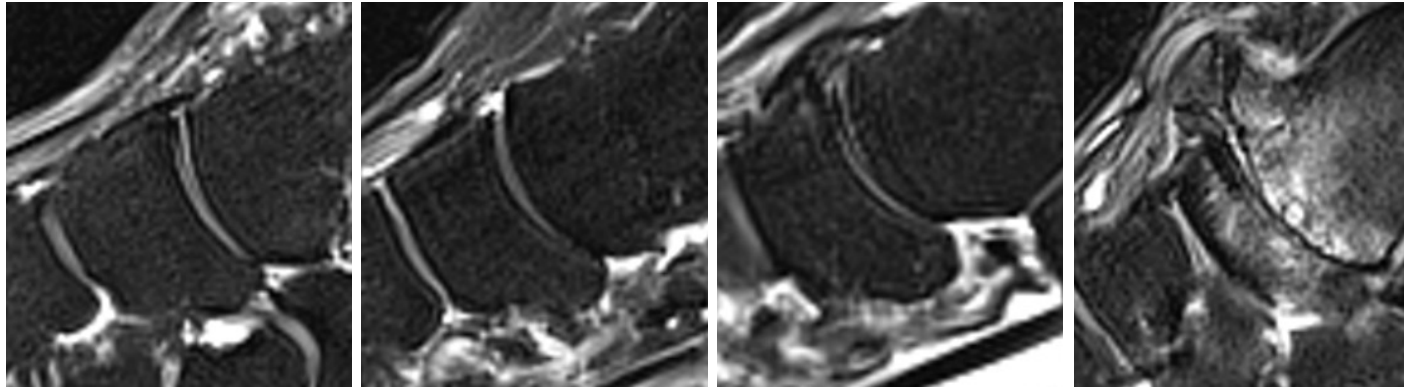
0

1

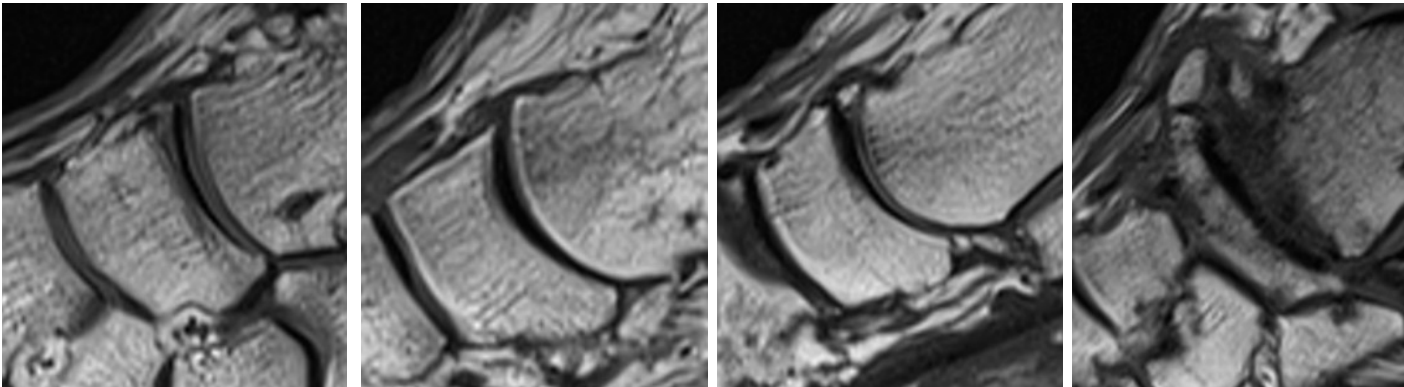
2

3

T2-weighted  
Sagittal plane



T1-weighted  
Sagittal plane



Tarsal Joints  
Talo-navicular Osteophytes

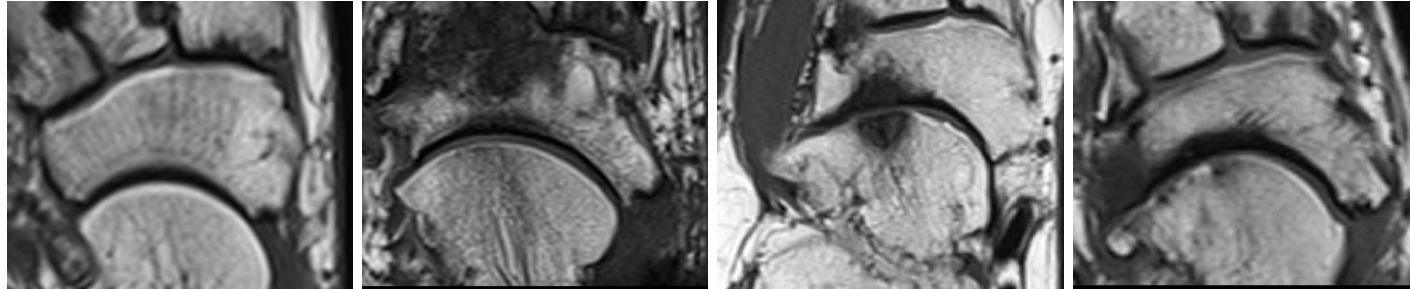
0

1

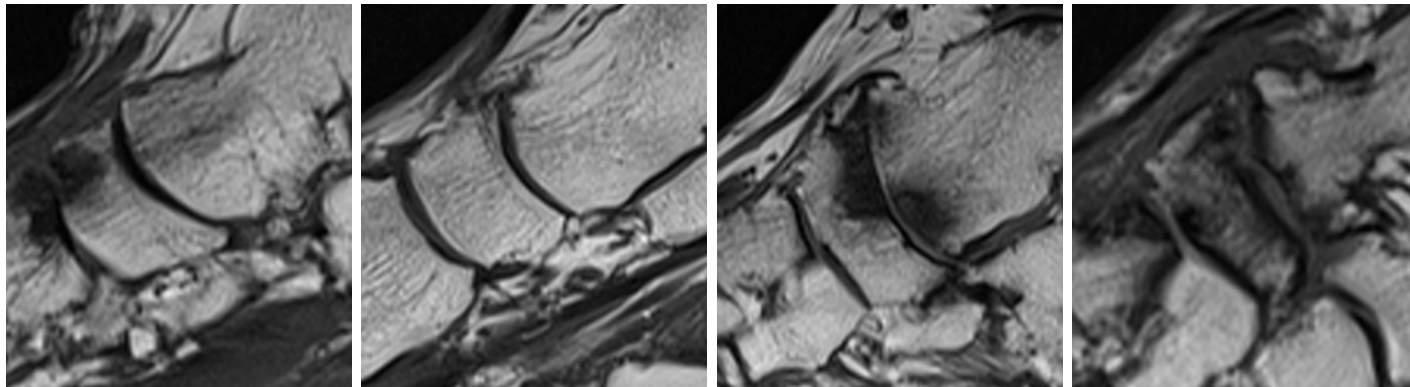
2

3

T1-weighted  
Long axis



T1-weighted  
Sagittal plane

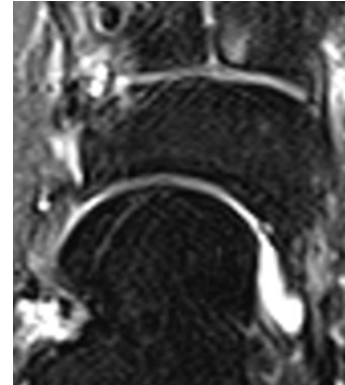
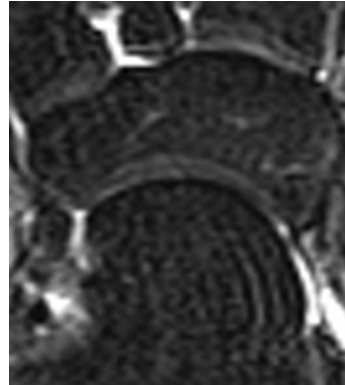


Tarsal Joints  
Talo-navicular Effusion-Synovitis

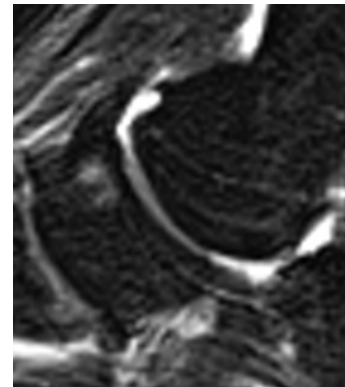
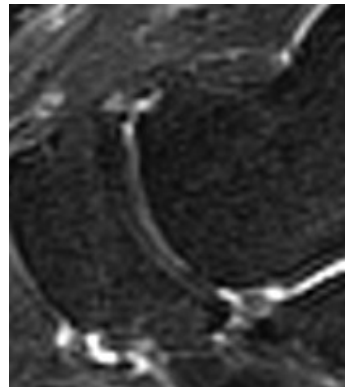
0

1

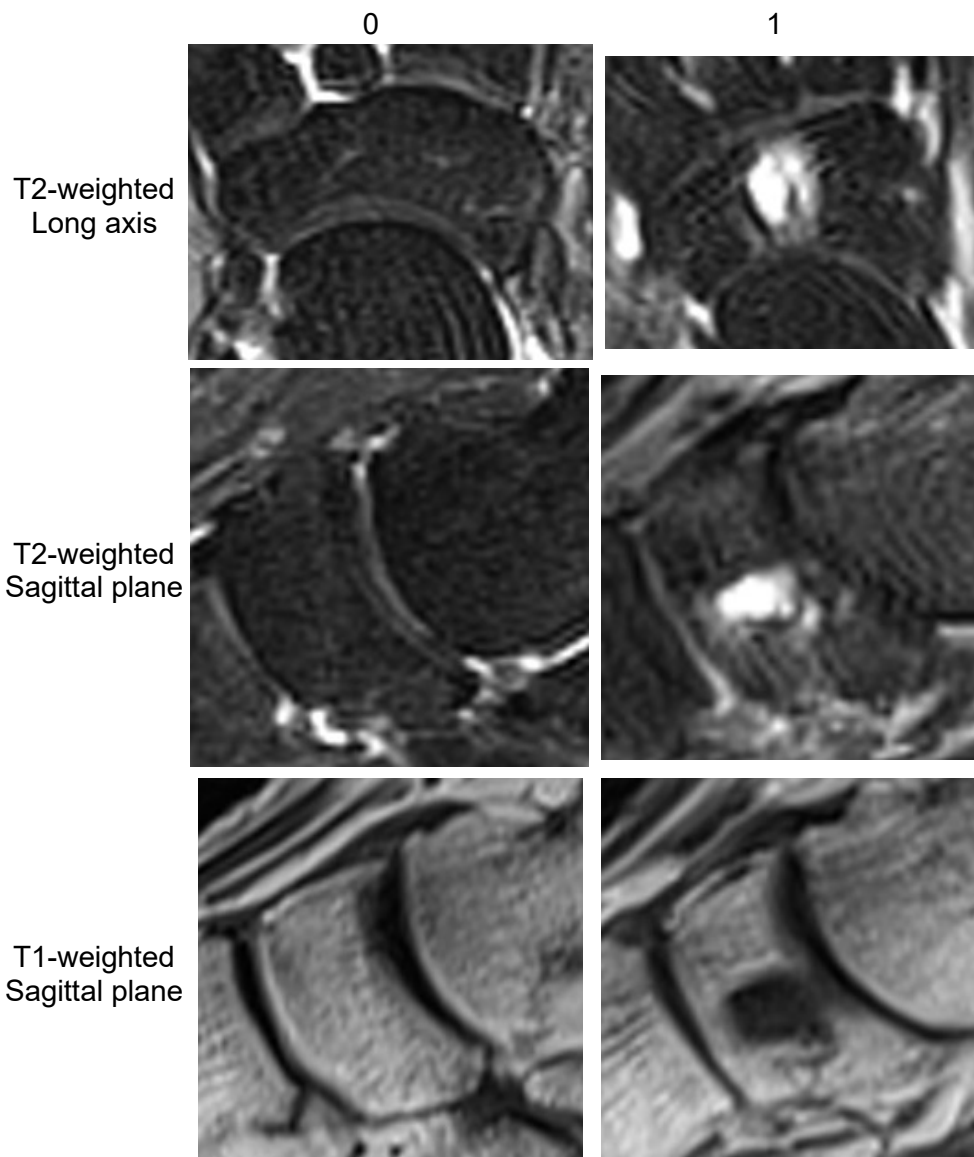
T2-weighted  
Long axis



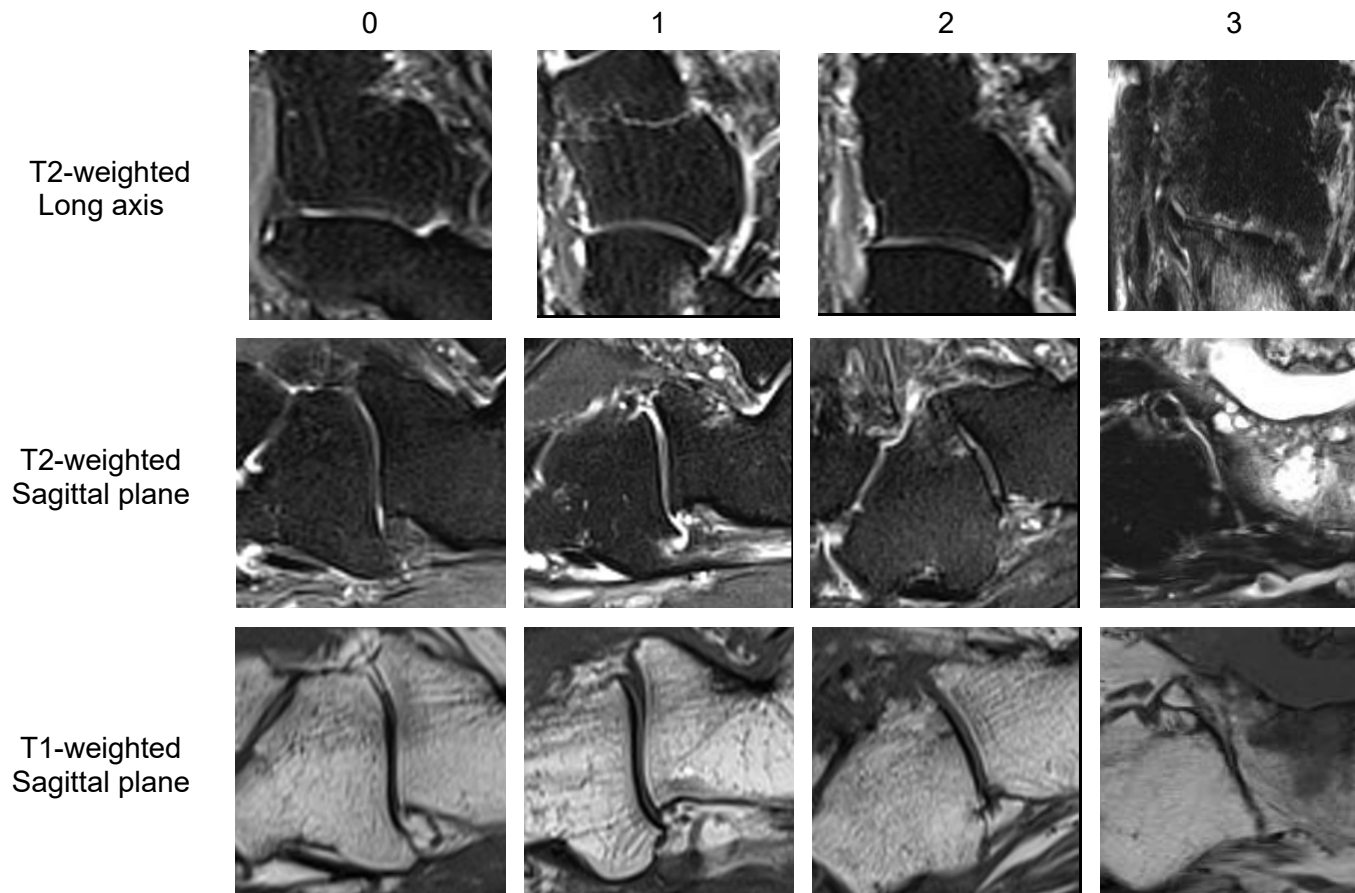
T2-weighted  
Sagittal plane



Tarsal Joints  
Talo-navicular Subchondral Cyst



Tarsal Joints  
Calcaneo-cuboid Joint Space Narrowing





Tarsal Joints  
Calcaneo-cuboid Osteophytes

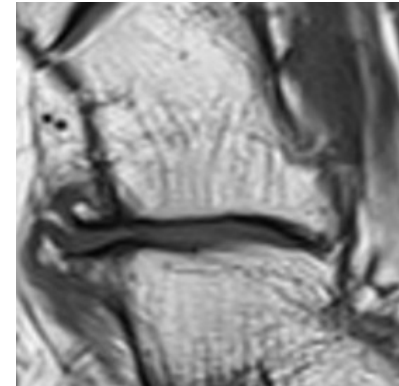
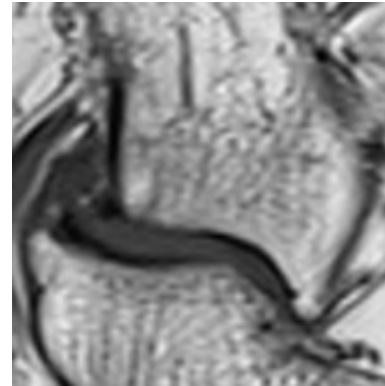
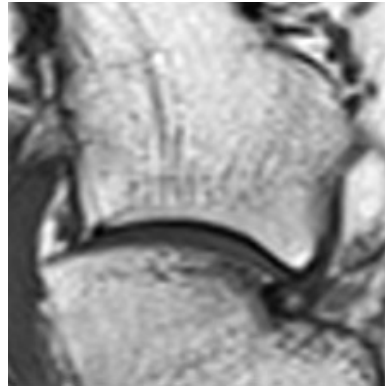
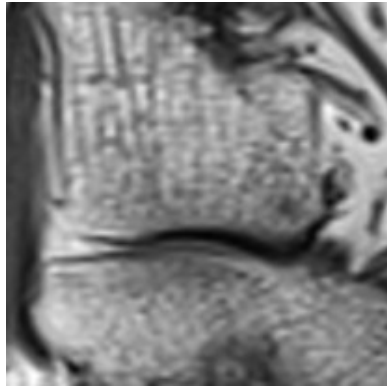
0

1

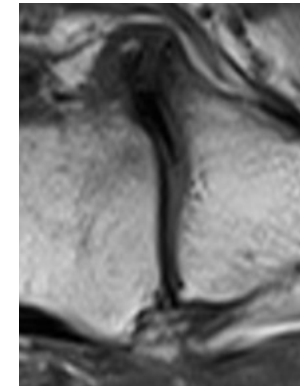
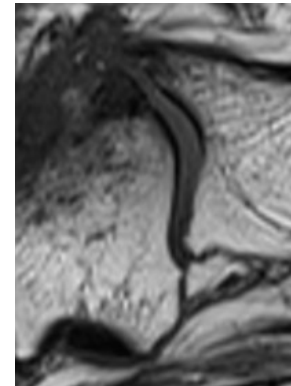
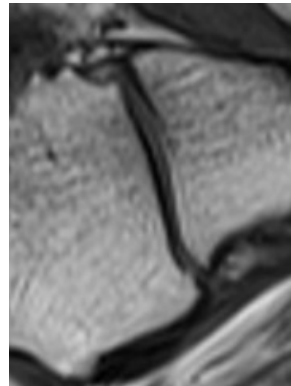
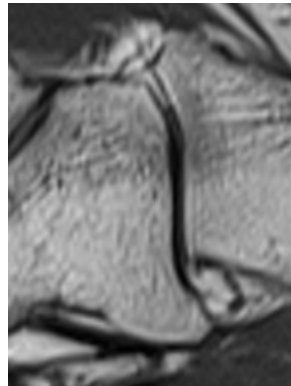
2

3

T1-weighted  
Long axis



T1-weighted  
Sagittal plane

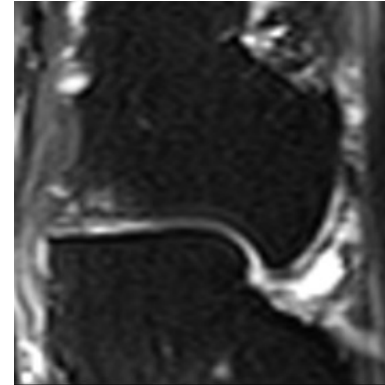
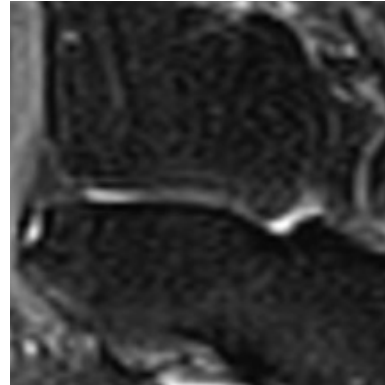


Tarsal Joints  
Calcaneo-cuboid Effusion-Synovitis

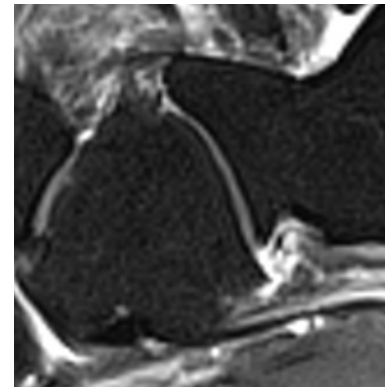
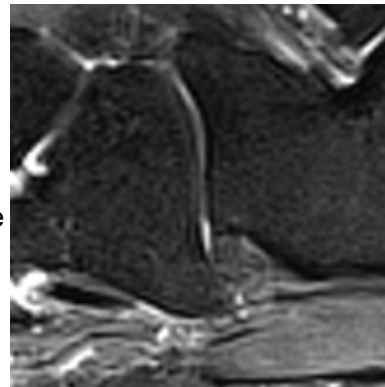
0

1

T2-weighted  
Long axis



T2-weighted  
Sagittal plane

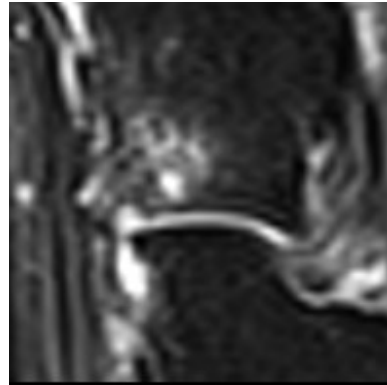
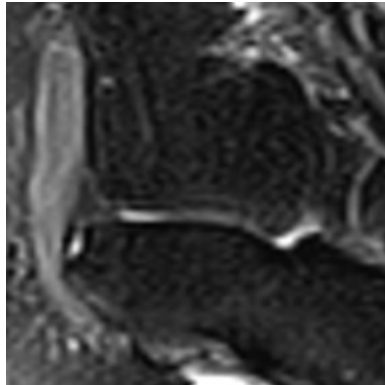


Tarsal Joints  
Calcaneo-cuboid Subchondral Cyst

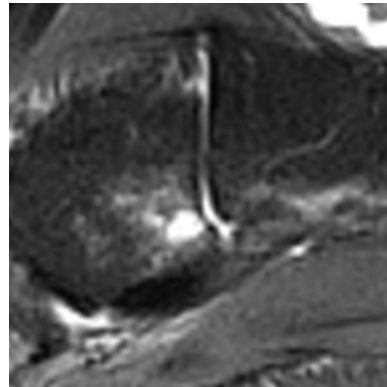
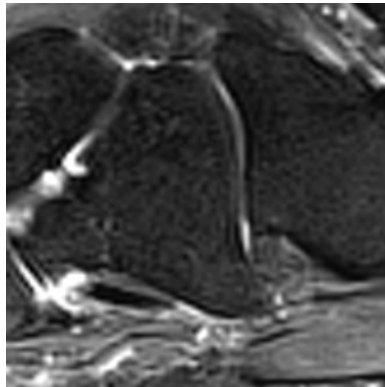
0

1

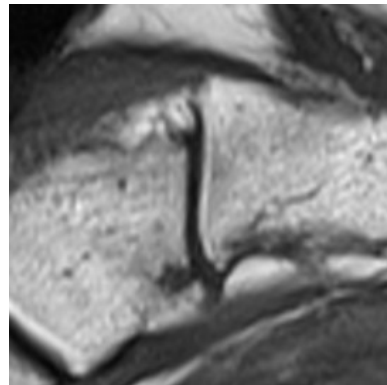
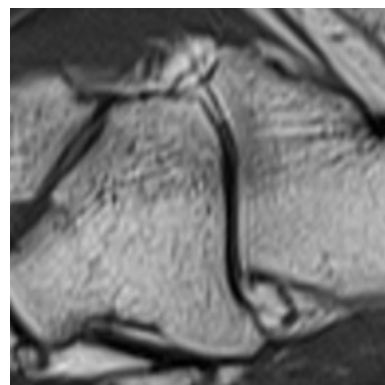
T2-weighted  
Long Axis



T2-weighted  
Sagittal plane



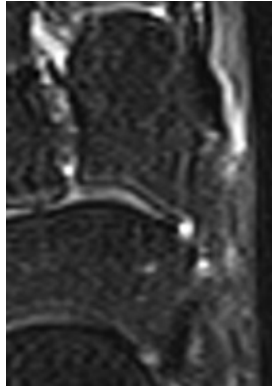
T1-weighted  
Sagittal plane



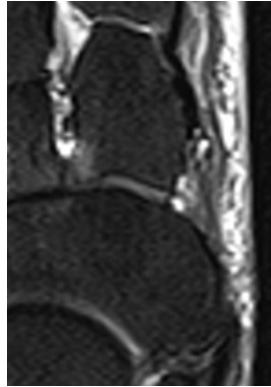


Tarsal Joints  
Naviculo-medial Cuneiform Joint Space Narrowing

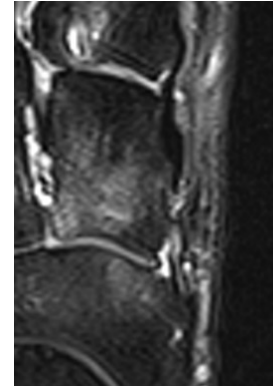
0



1



2

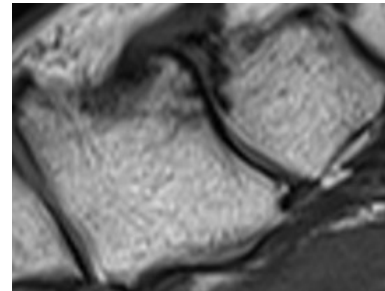
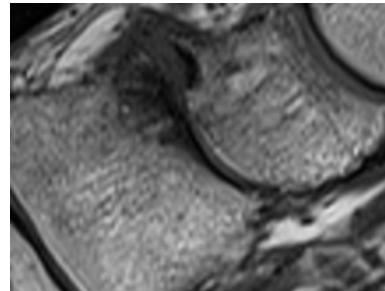


3



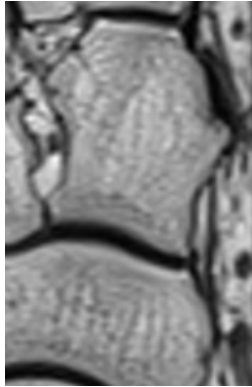
T2-weighted  
Long axis

T1-weighted  
Sagittal plane

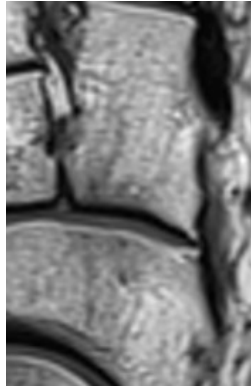


Tarsal Joints  
Naviculo-medial Cuneiform Osteophytes

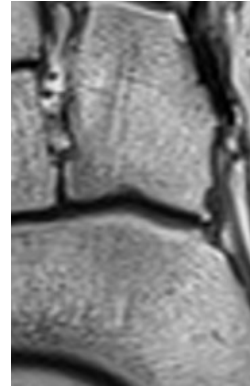
0



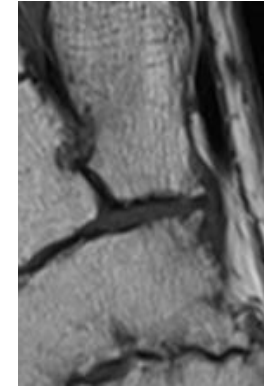
1



2

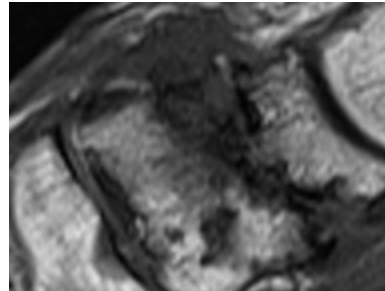



3



T1-weighted  
Long axis

T1-weighted  
Sagittal plane

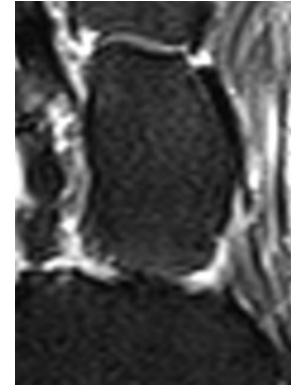
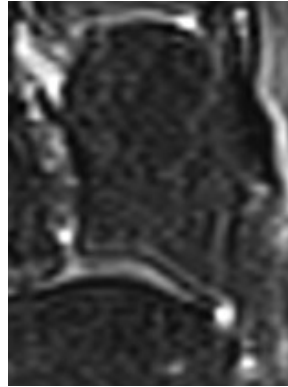
Tarsal Joints  
Naviculo-medial Cuneiform Effusion-Synovitis

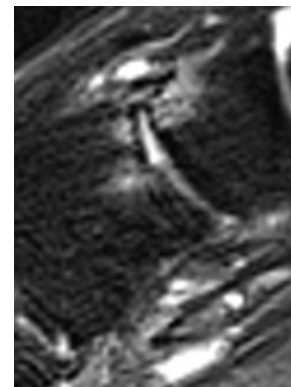
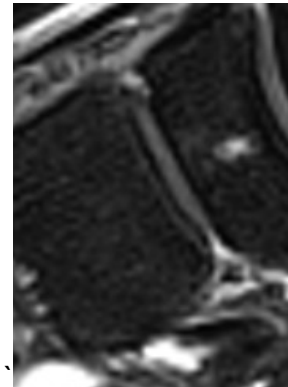
0

1

T2-weighted  
Long axis



T2-weighted  
Sagittal plane

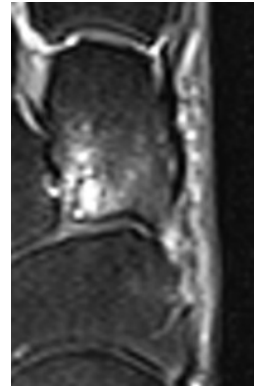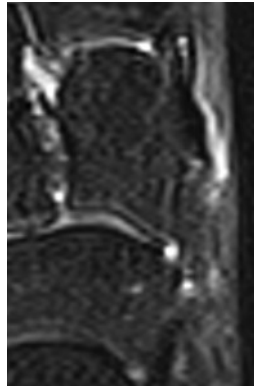


Tarsal Joints  
Naviculo-medial Cuneiform Subchondral Cyst

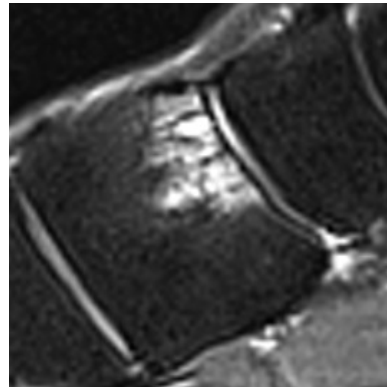
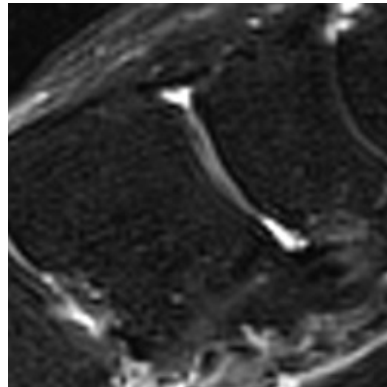
0

1


T2-weighted  
Long axis



T2-weighted  
Sagittal plane



T1-weighted  
Sagittal plane



Tarsal Joints  
Naviculo-intermediate Cuneiform Joint Space Narrowing

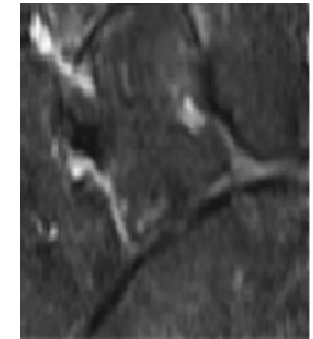
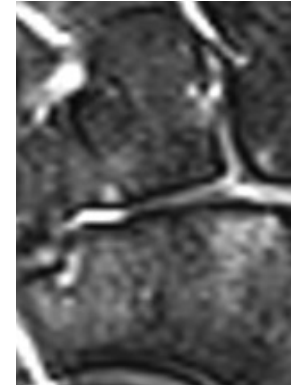
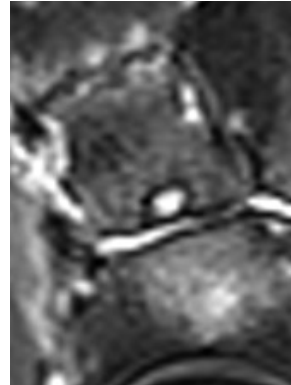
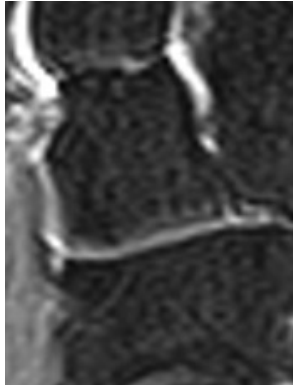
0

1

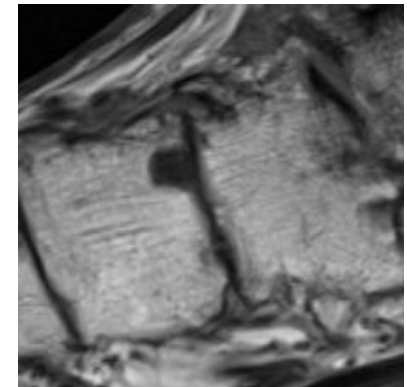
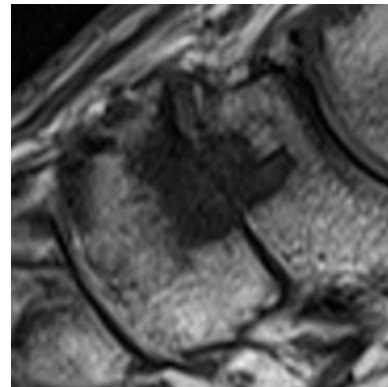
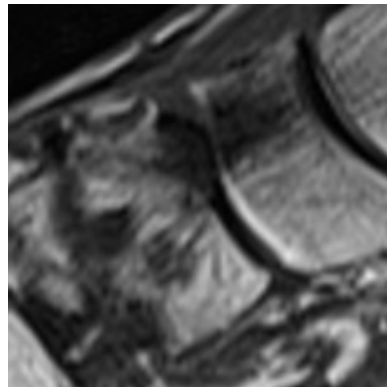
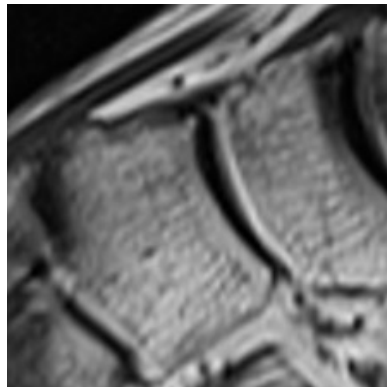
2

3

T2-weighted  
Long axis

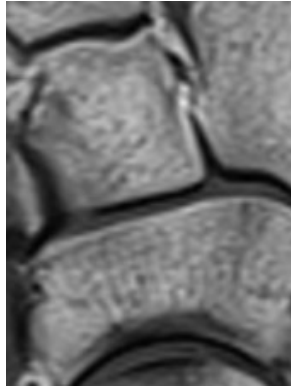


T1-weighted  
Sagittal plane

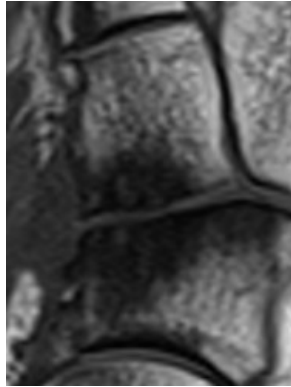


Tarsal Joints  
Naviculo-intermediate Cuneiform Osteophytes

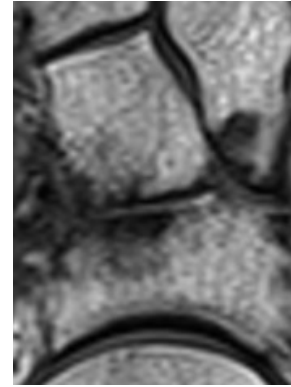
0



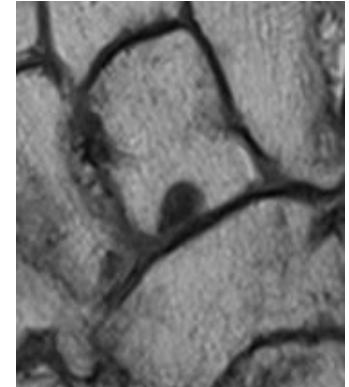
1



2

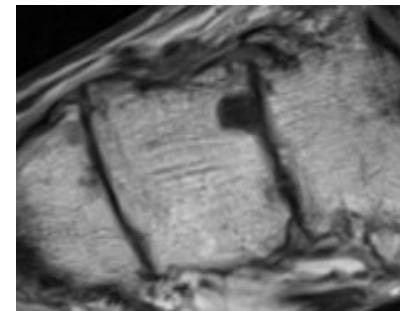
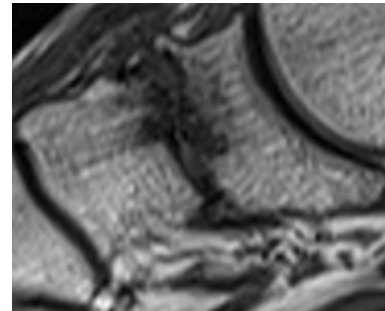
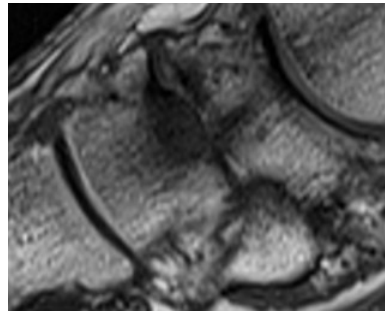
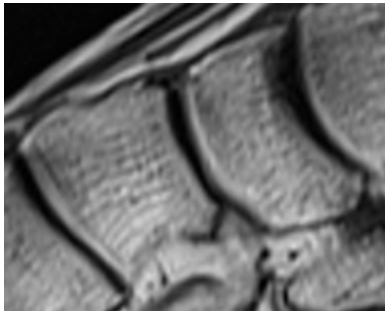


3



T1-weighted  
Long axis

T1-weighted  
Sagittal plane

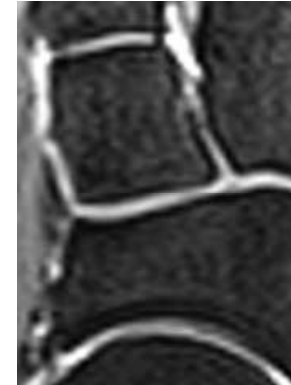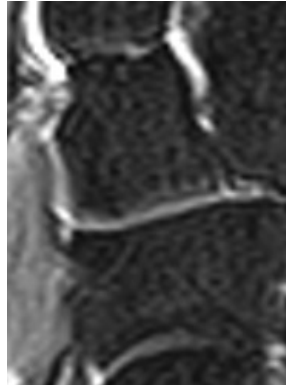


Tarsal Joints  
Naviculo-intermediate Cuneiform Effusion-Synovitis

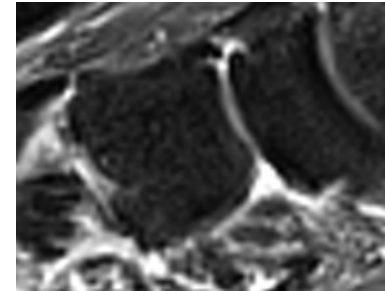
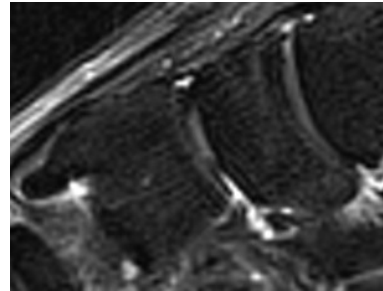
0

1

T2-weighted  
Long axis



T2-weighted  
Sagittal plane



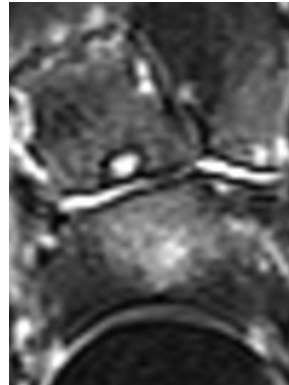
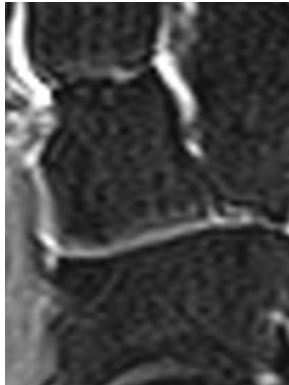


Tarsal Joints  
Naviculo-intermediate Cuneiform Subchondral Cyst

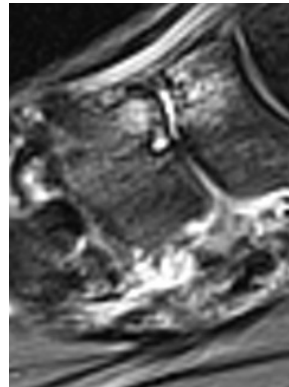
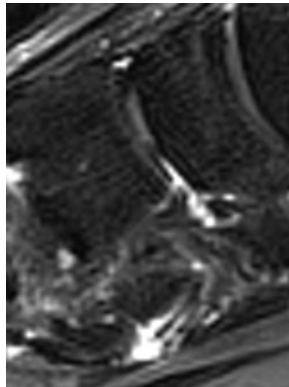
0

1

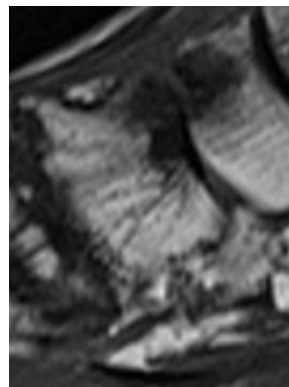
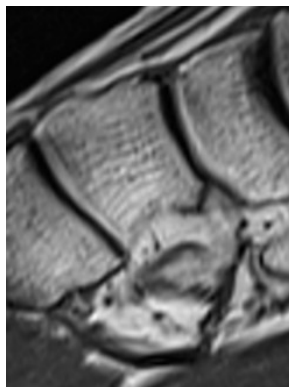
T2-weighted  
Long axis



T2-weighted  
Sagittal plane



T1-weighted  
Sagittal plane





Tarsal Joints  
Naviculo-lateral Cuneiform Joint Space Narrowing

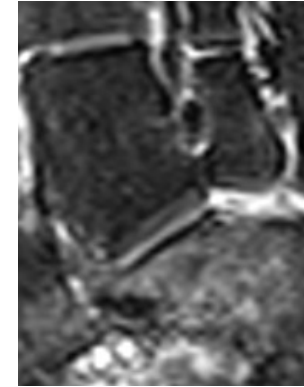
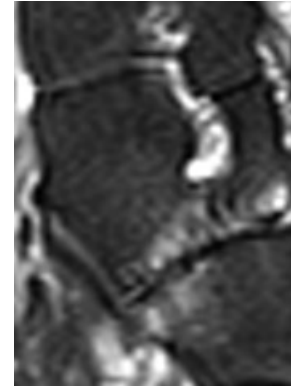
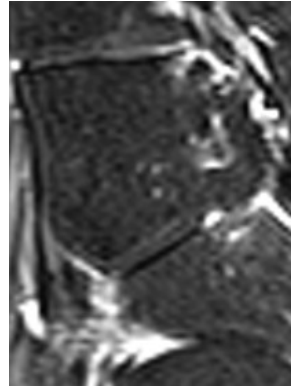
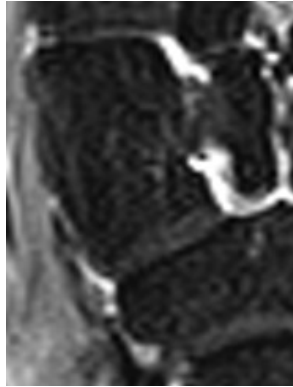
0

1


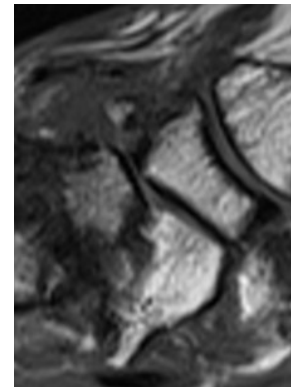
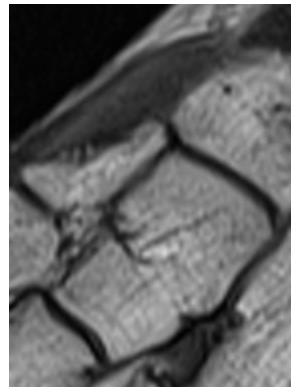

2

3

T2-weighted  
Long axis



T1-weighted  
Sagittal plane



Tarsal Joints  
Naviculo-lateral Cuneiform Osteophytes

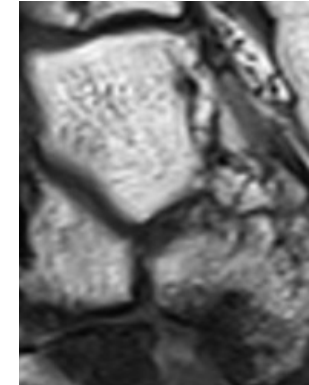
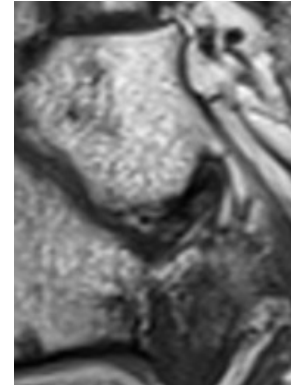
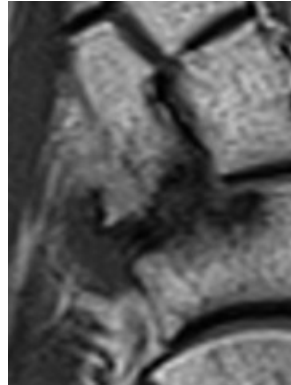
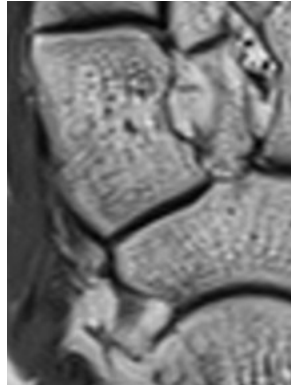
0

1


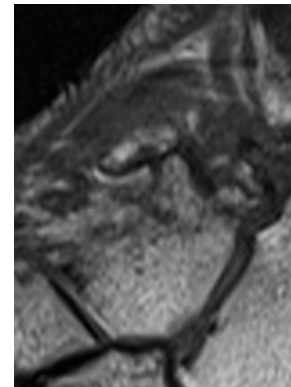
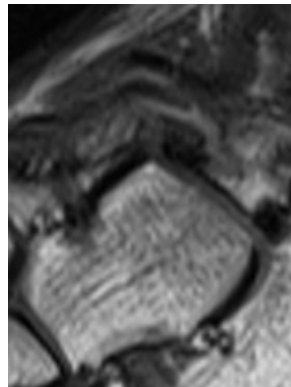
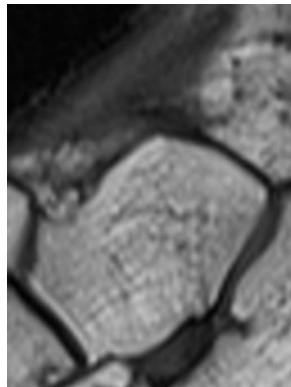
2

3

T1-weighted  
Long axis



T1-weighted  
Sagittal plane

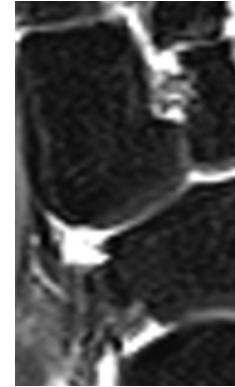
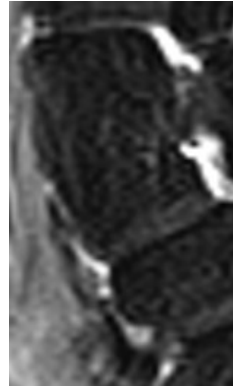


Tarsal Joints  
Naviculo-lateral Cuneiform Effusion-Synovitis

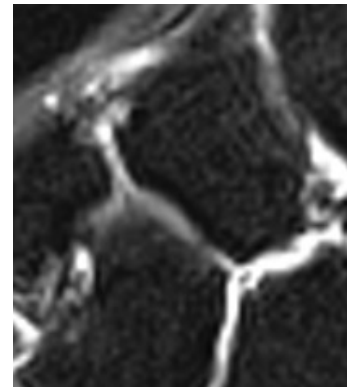
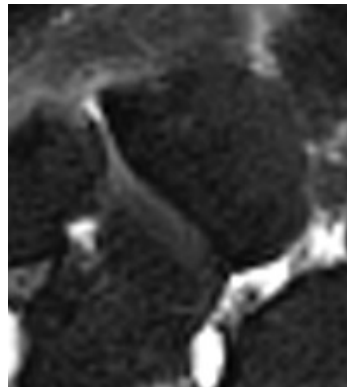
0

1

T2-weighted  
Long axis



T2-weighted  
Sagittal plane

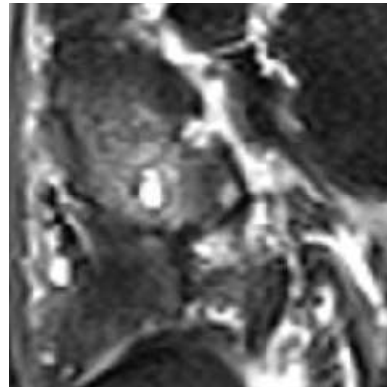
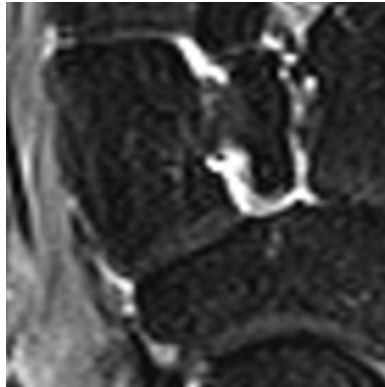


Tarsal Joints  
Naviculo-lateral Cuneiform Subchondral Cyst

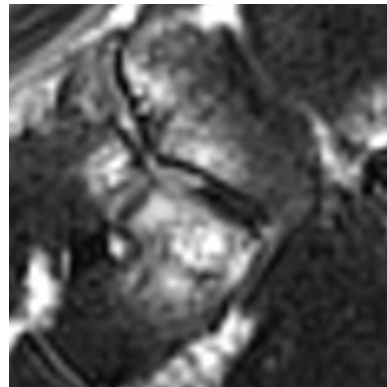
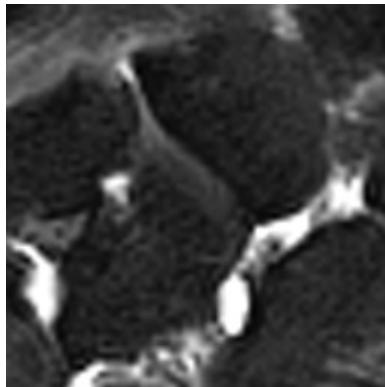
0

1

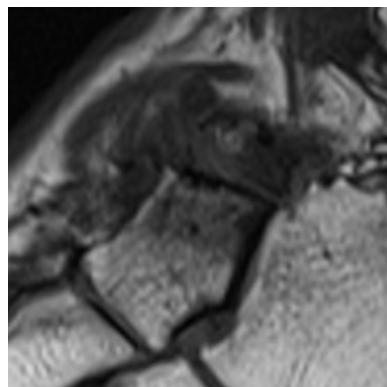
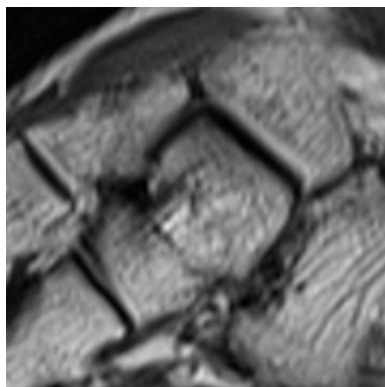
T2-weighted  
Long axis



T2-weighted  
Sagittal plane



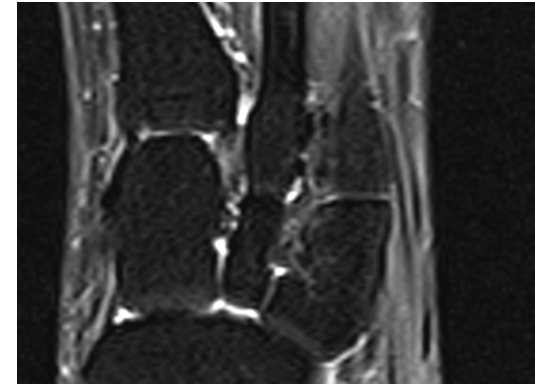
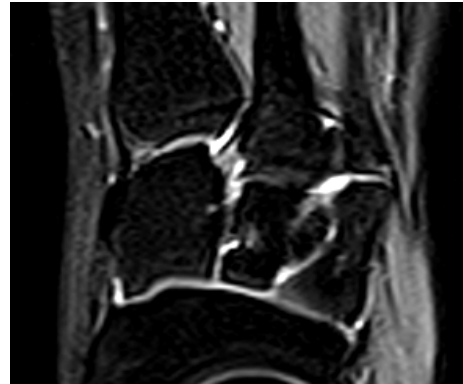
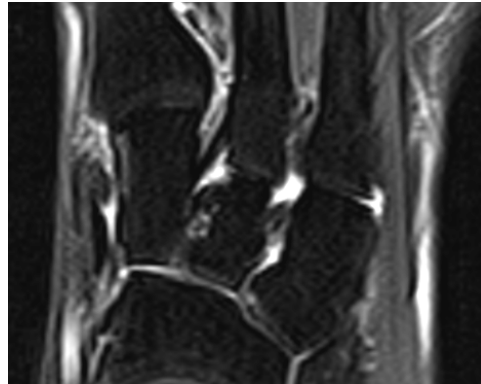
T1-weighted  
Sagittal plane



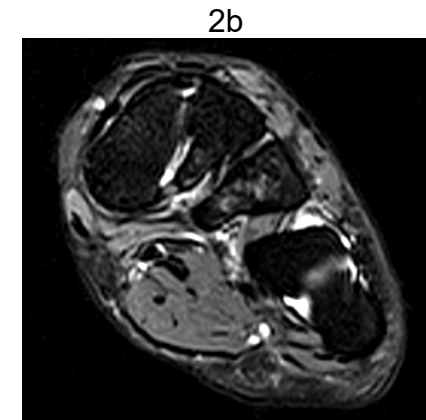
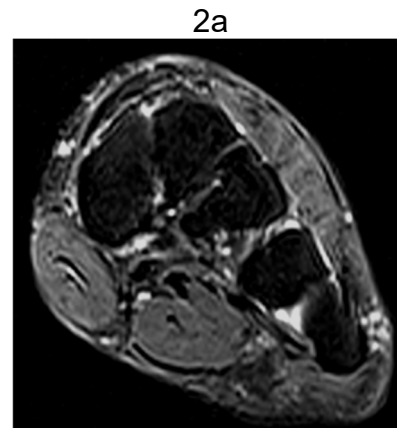
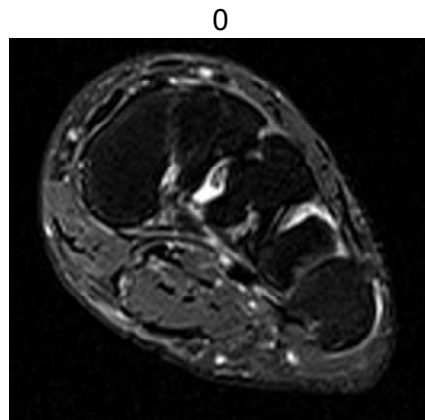
## Chapter 4. Soft Tissue

Ligament Abnormality Scores  
Lisfranc (1a and 1b) and Intertarsal ligaments (2a and 2b)

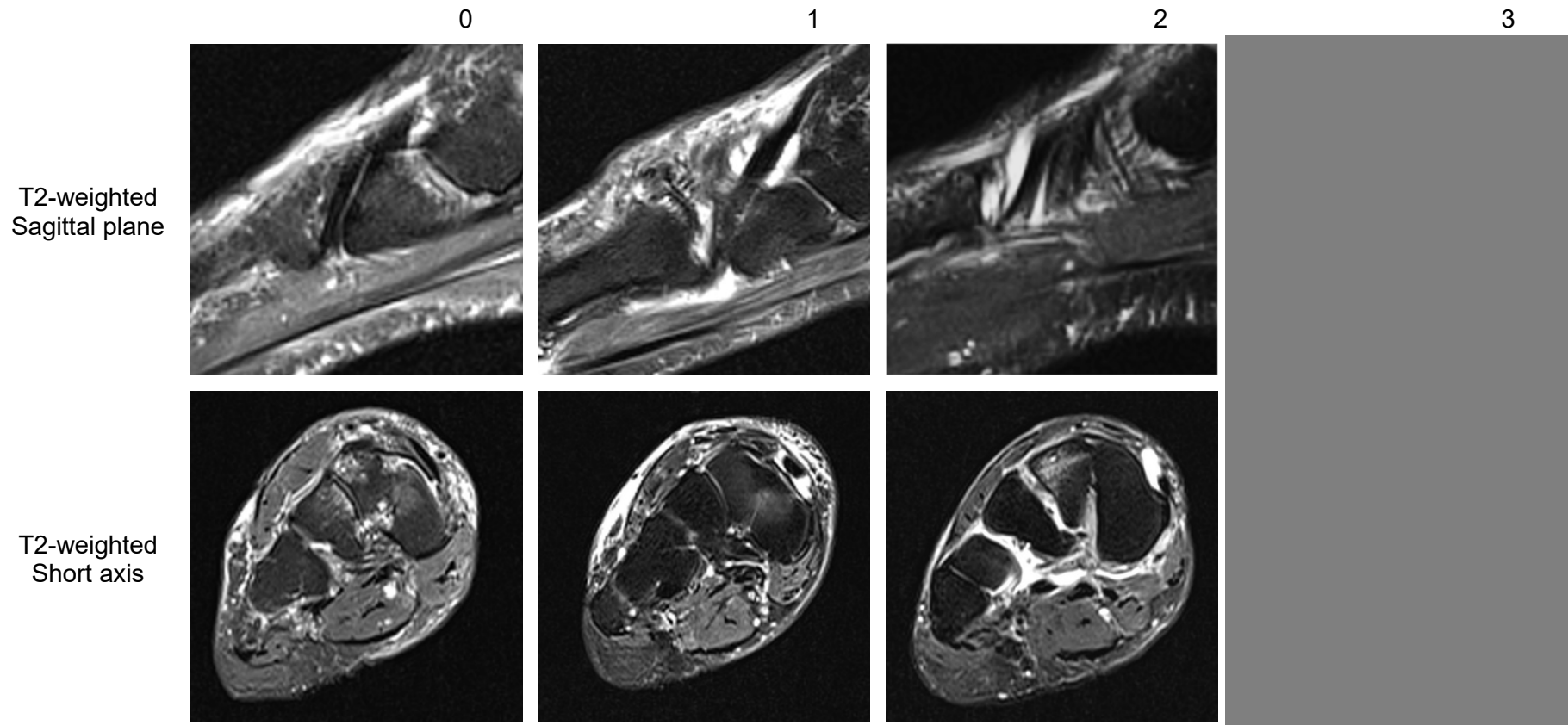
T2-weighted  
Long axis



T2-weighted  
Short axis

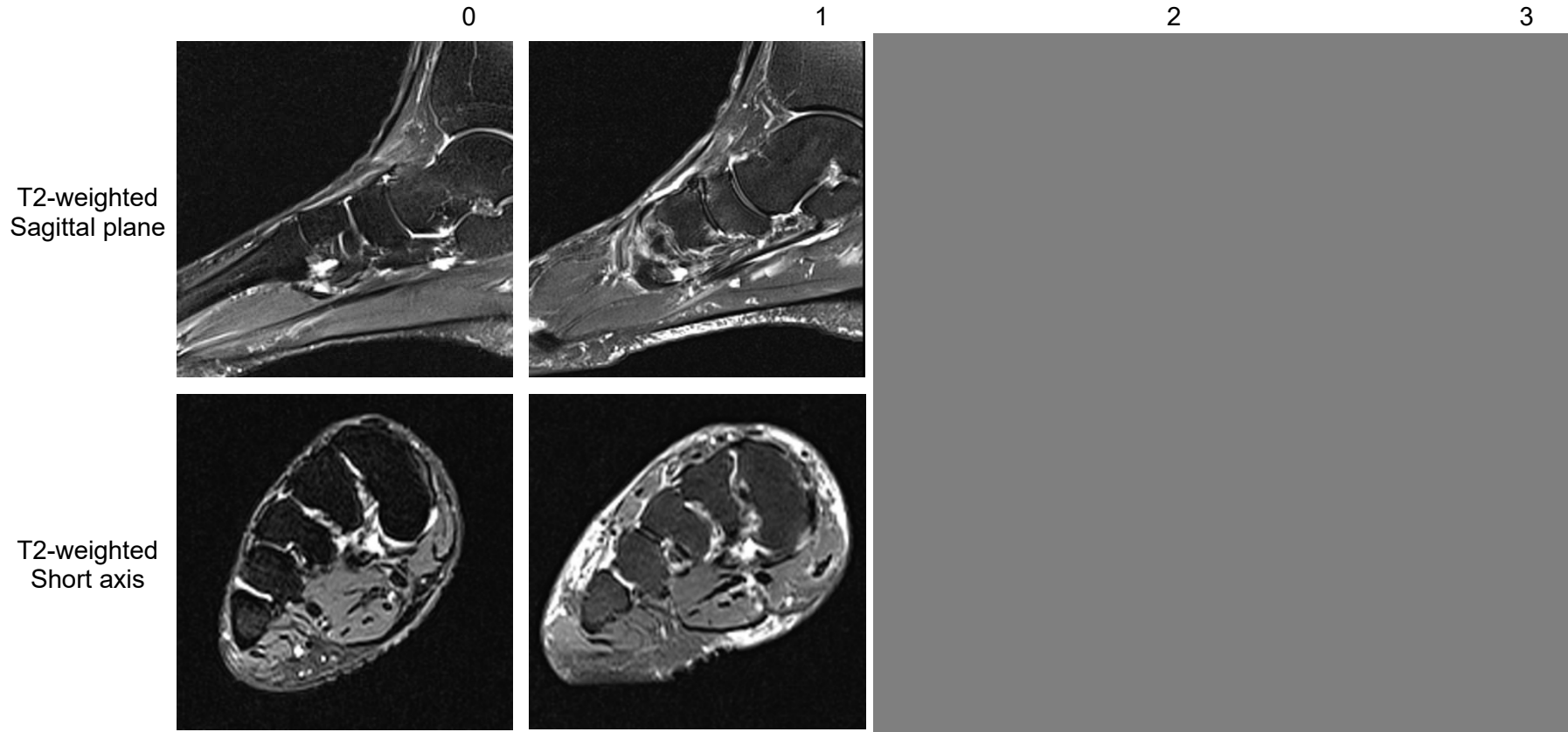


Tenosynovitis  
Tibialis Anterior





Tenosynovitis  
Extensor Hallucis Longus



Tenosynovitis  
Extensor Digitorum Longus


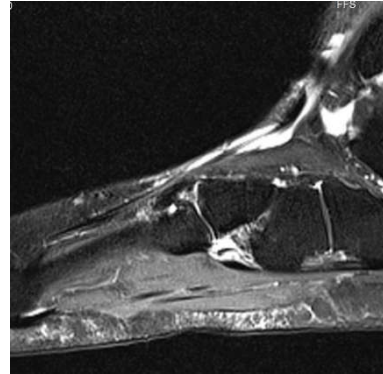
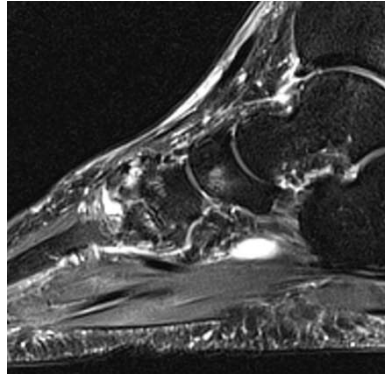
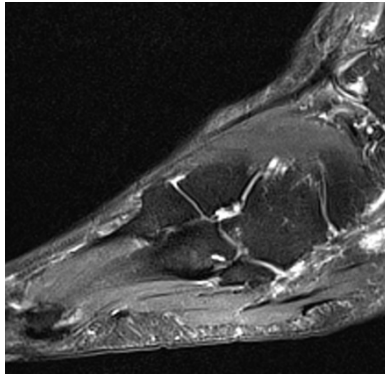
0

1

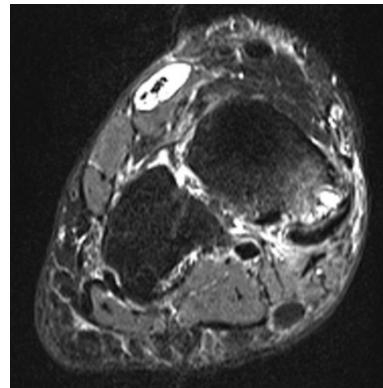
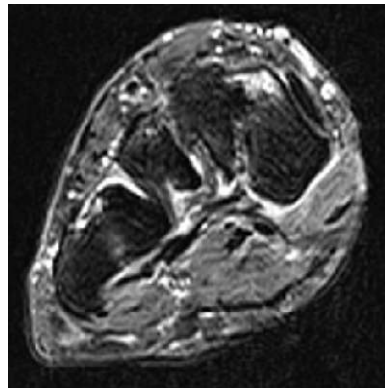
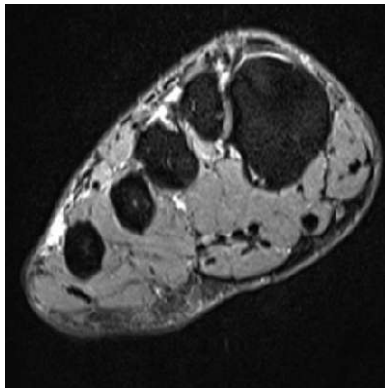
2

3

T2-weighted  
Sagittal  
plane



T2-weighted  
Short axis



Tenosynovitis  
Peroneus Brevis

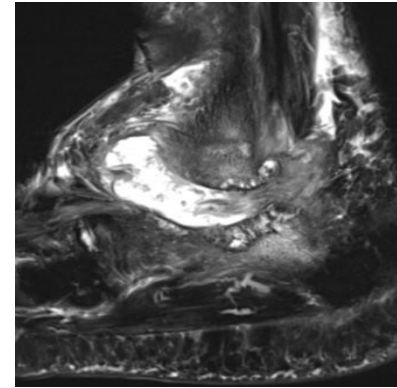
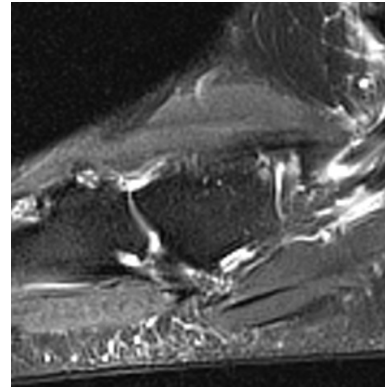
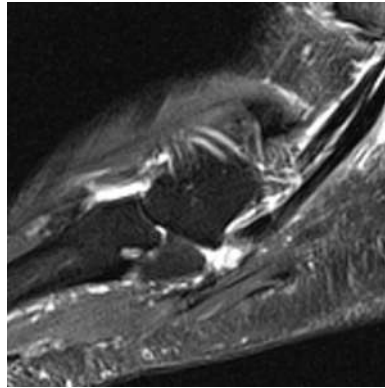
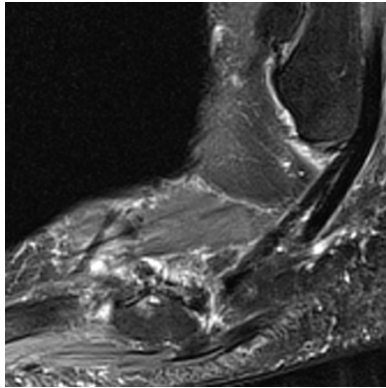
0

1

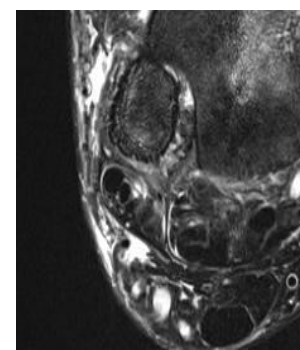
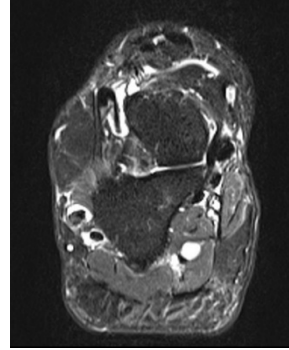
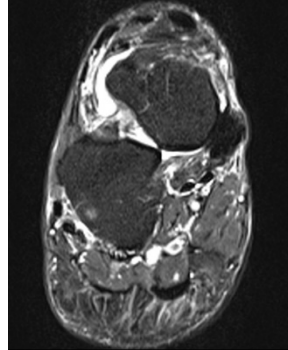
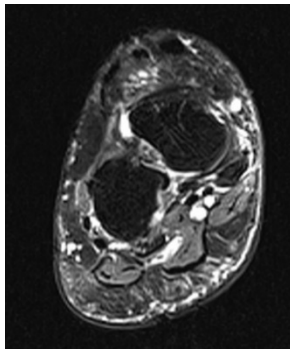
2

3

T2-weighted  
Sagittal plane



T2-weighted  
Short axis



Tenosynovitis  
Peroneus Longus

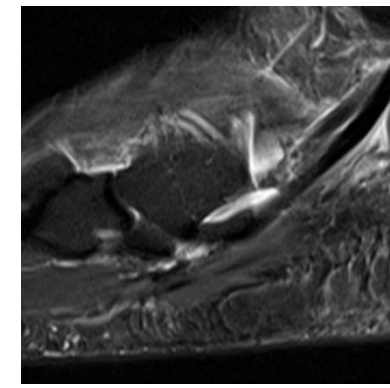
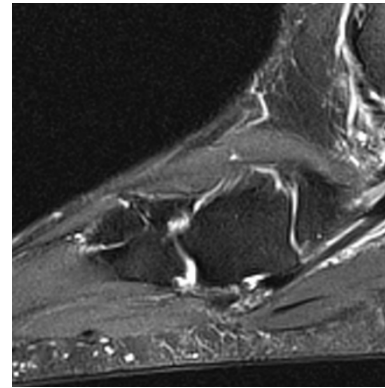
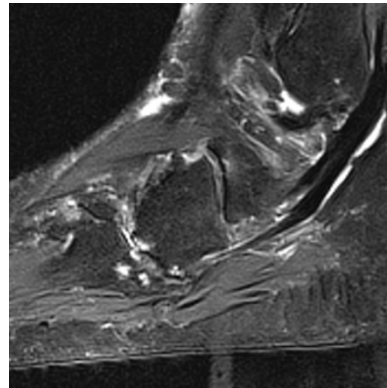
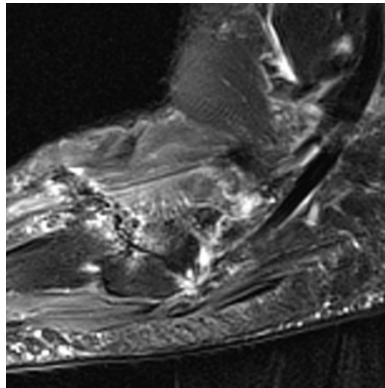
0

1

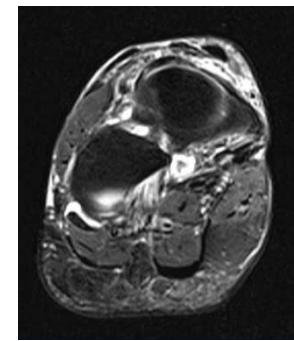
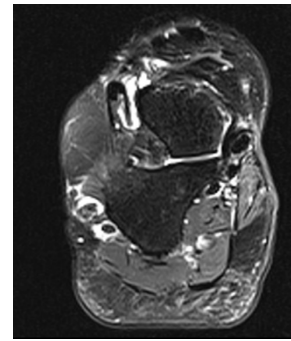
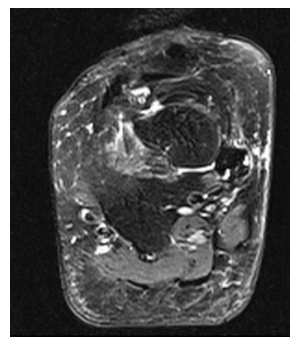
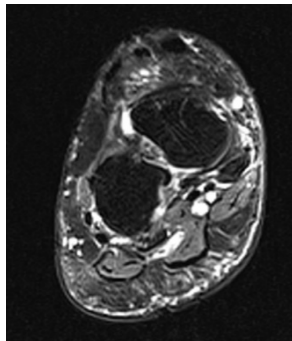
2

3

T2-weighted  
Sagittal plane

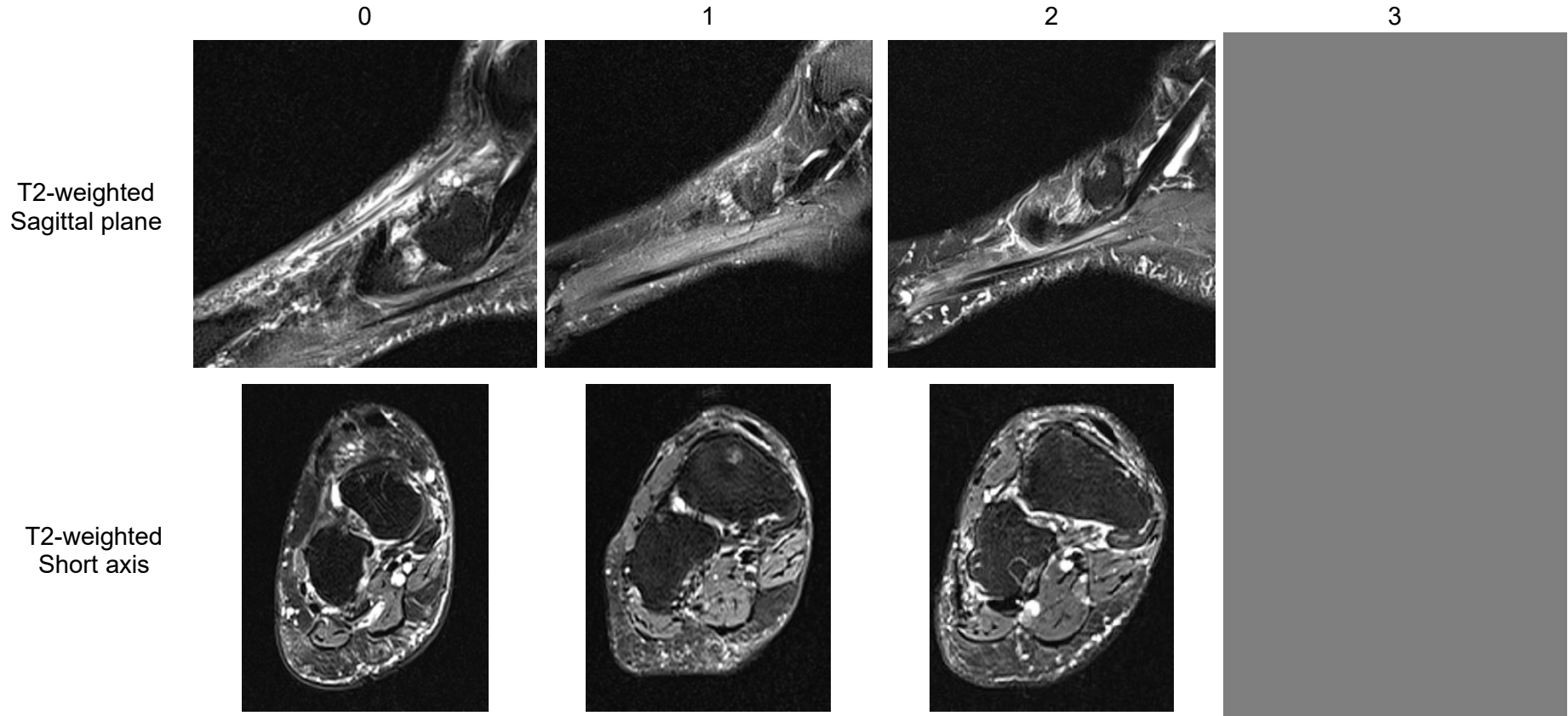


T2-weighted  
Short axis





Tenosynovitis  
Tibialis Posterior



Tenosynovitis  
Flexor Digitorum Longus


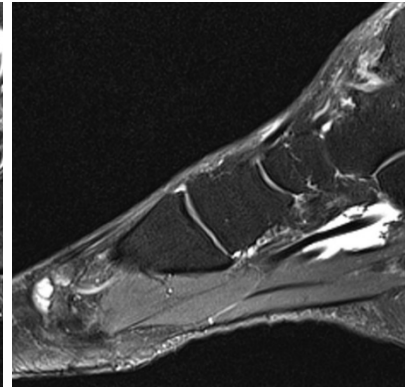
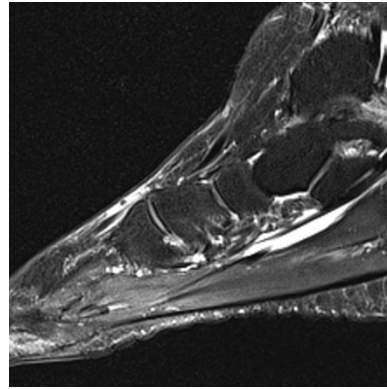
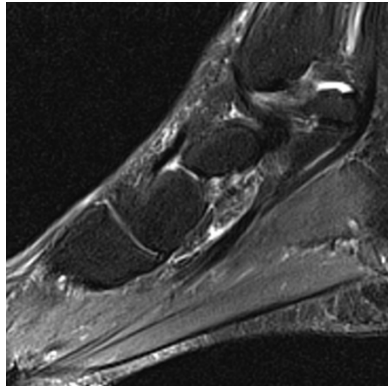
0

1


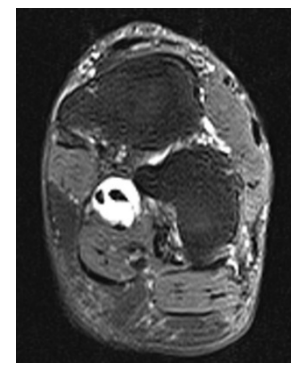
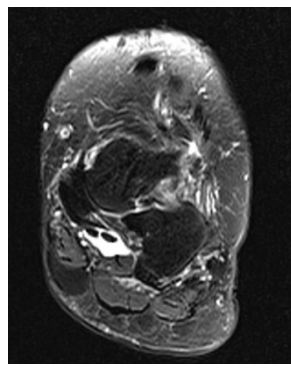
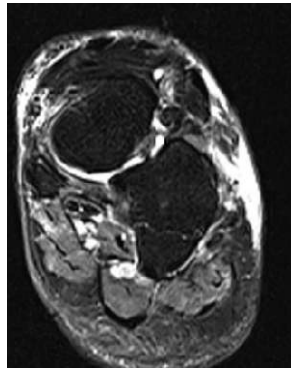
2

3

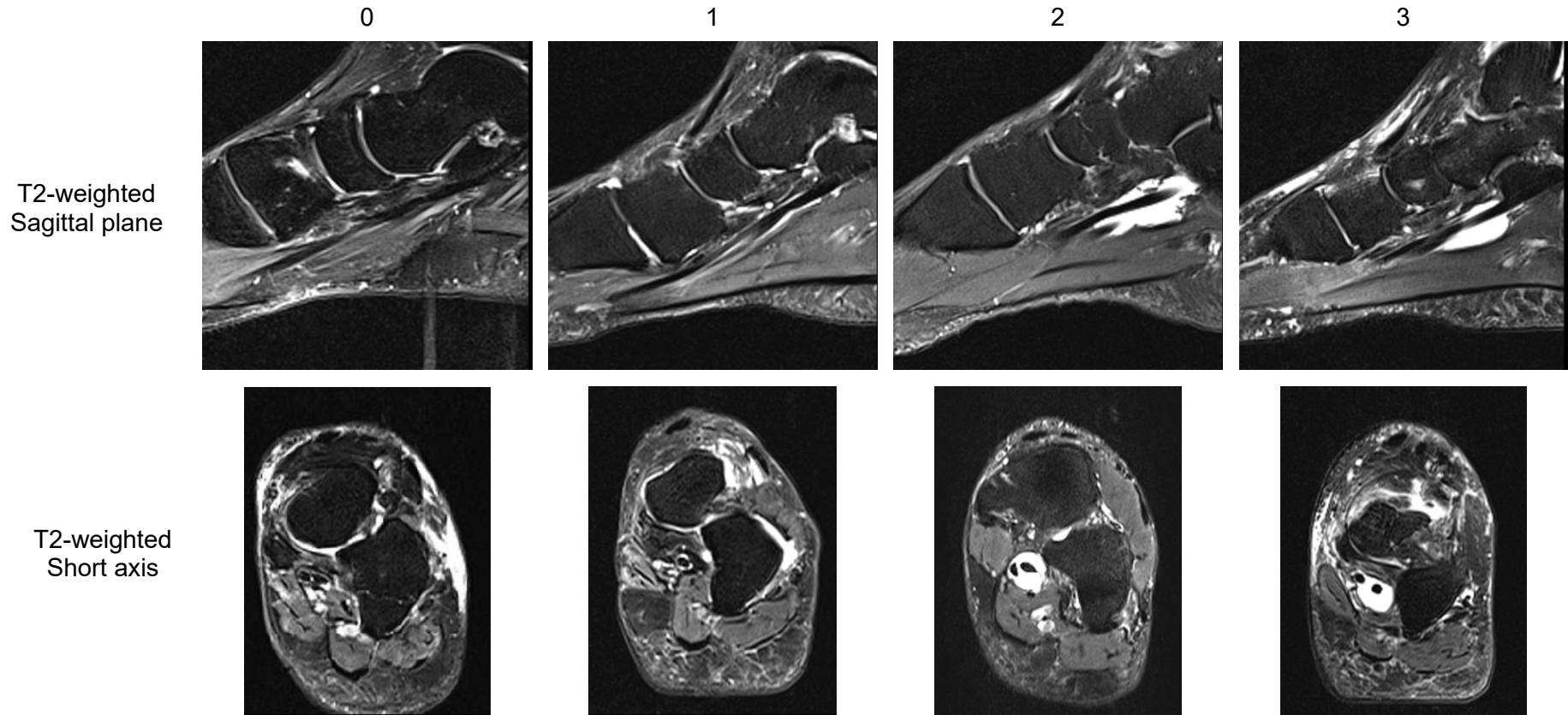
T2-weighted  
Sagittal plane



T2-weighted  
Short axis

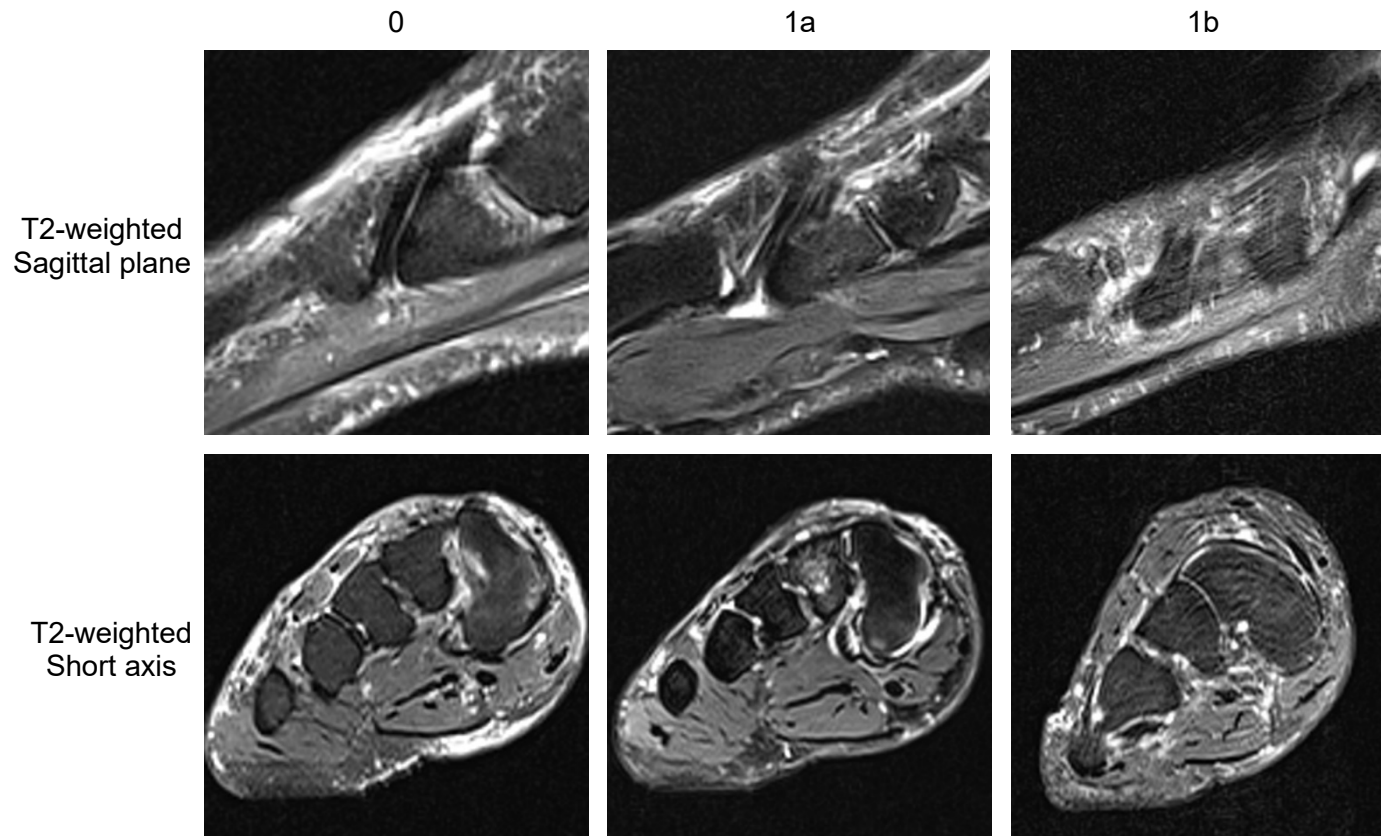


Tenosynovitis  
Flexor Hallucis Longus

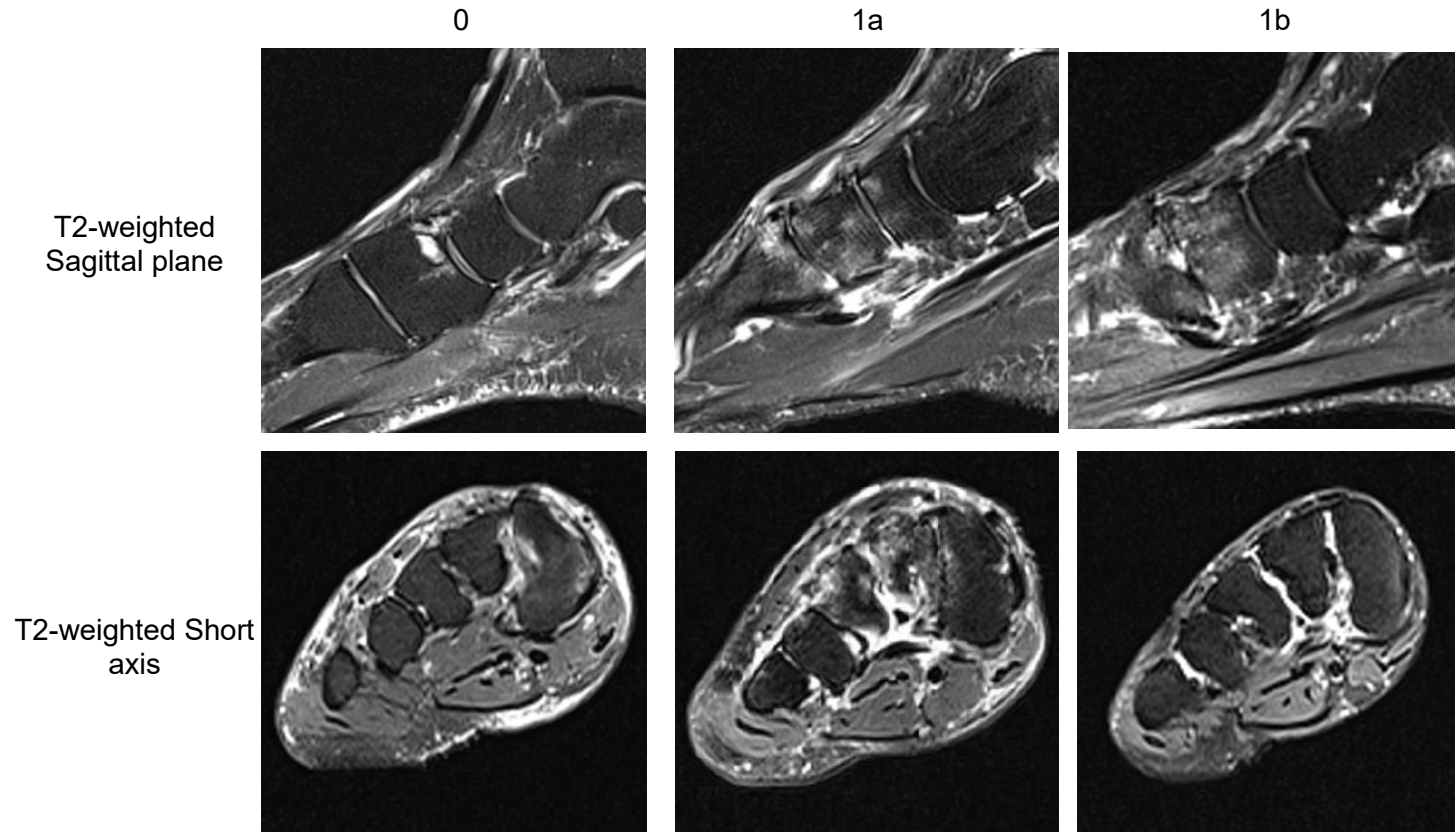




Enthesopathy Scores  
Tibialis Anterior 1st Metatarsal (1a) and Medial Cuneiform (1b)



Enthesopathy Scores  
Peroneus Longus 1st Metatarsal (1a) and Medial Cuneiform (1b)

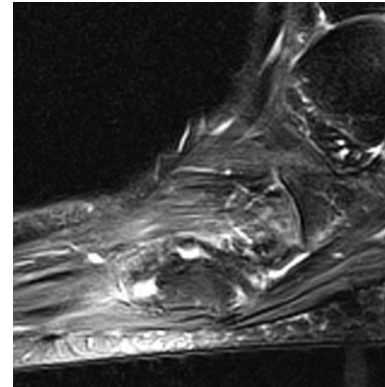
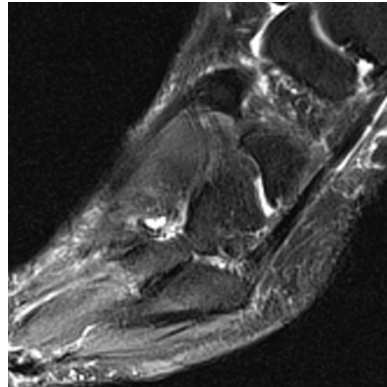


Enthesopathy Scores  
Peroneus Brevis Base of 5th Metatarsal

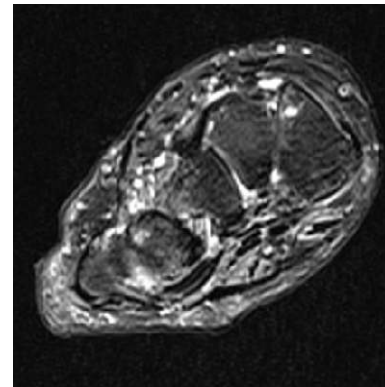
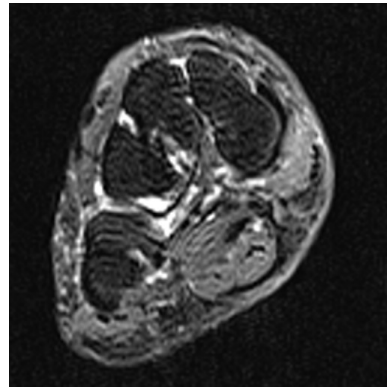
0

1

T2-weighted  
Sagittal plane



T2-weighted  
Short axis



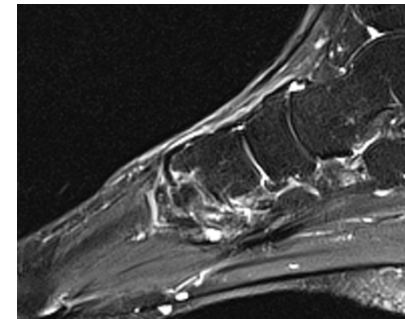
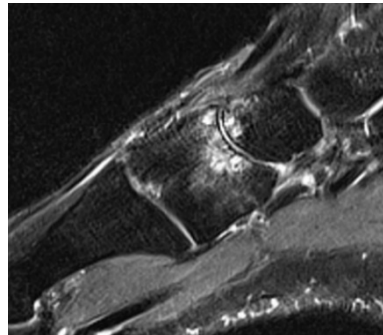
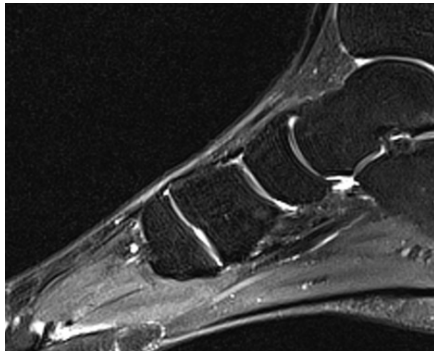
Enthesopathy Scores  
Tibialis Posterior Medial Cuneiform (1a) and 2/3/4 Metatarsal (1b)

0

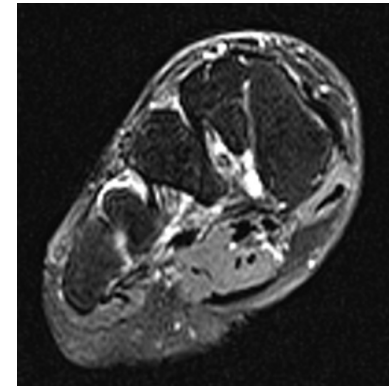
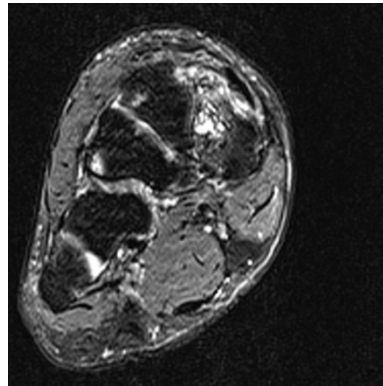
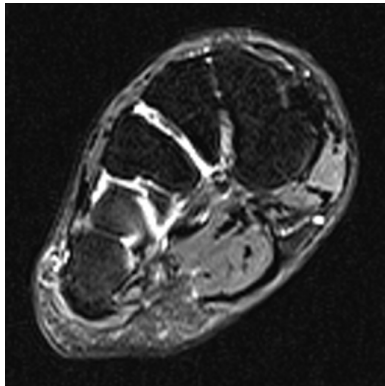
1a

1b

T2-weighted  
Sagittal plane

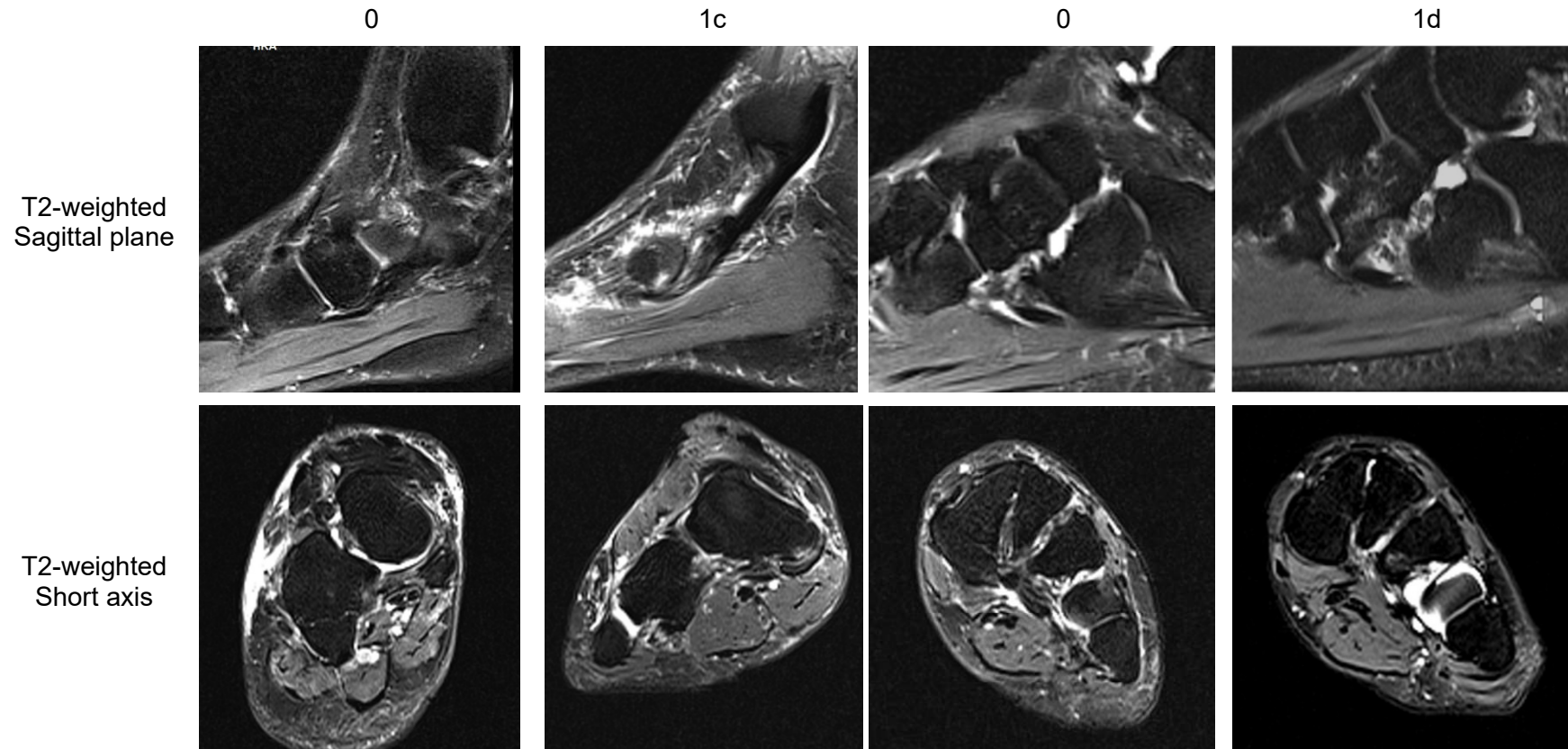


T2-weighted  
Short axis

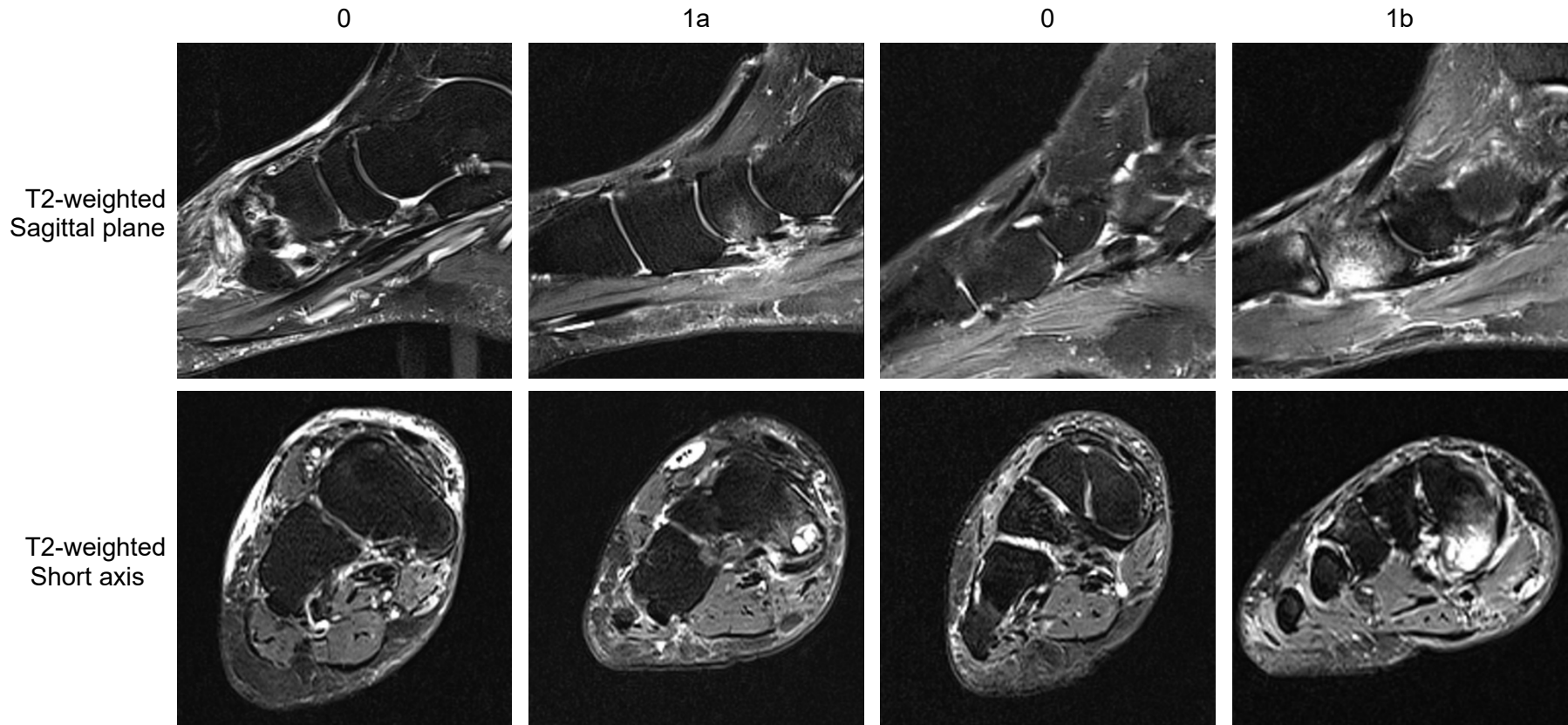




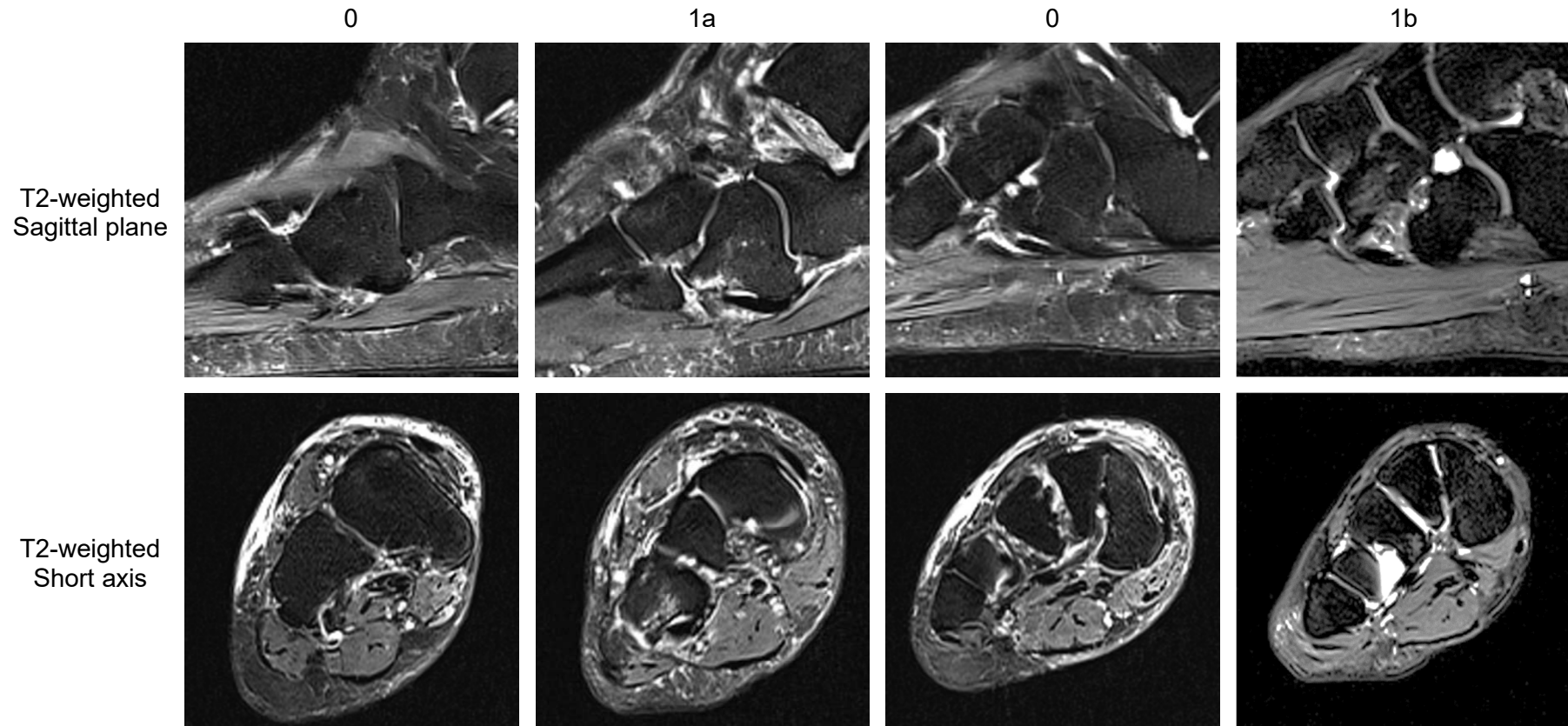
Enthesopathy Scores  
Tibialis Posterior Navicular (1c) and Lateral Cuneiform (1d)



Sub Tendon Bone Marrow Lesion (Tendon Groove)  
Tibialis Posterior Navicular (1a) Medial Cuneiform (1b)



Sub Tendon Bone Marrow Lesion (Tendon Groove)  
Peroneus Longus Cuboid (1a) and Lateral Cuneiform (1b)



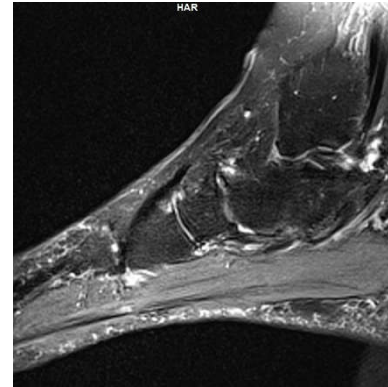
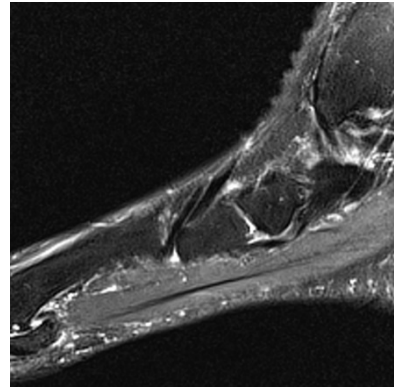


Sub Tendon Bone Marrow Lesion (Tendon Groove)  
Tibialis Anterior Medial Cuneiform

0

1

T2-weighted  
Sagittal plane



T2-weighted  
Short axis

